

Botryoid Rhabdomyosarcoma of Nasopharynx: Case Report and Literature Review

Merzouqi B^{1*}, Salama K¹, Lahjaouj M¹, Rouadi S², Abada R², Roubal M² and Mahtar M²

¹Department of ENT, 20 August Hospital, Ibn Rochd University Hospital, Casablanca, Moroc

²Department of ENT, 20 August Hospital, Ibn Rochd University Hospital, Faculty of Medicine and Pharmacy, Casablanca, Morocco

***Corresponding Author:** Merzouqi Boutaina, Department of ENT, 20 August Hospital, Ibn Rochd University Hospital, Casablanca, Morocco.

Received: January 02, 2021; **Published:** April 26, 2021

Abstract

Rhabdomyosarcoma (RMS) is a rare and aggressive malignancy originating from primitive mesenchymal cells that arise anywhere in the body, including sites where striate muscle is not found or scanty. RaMS is the most common type of soft-tissue sarcoma in young children, representing 5% of all childhood malignancies. Almost half of RMS occur in the head and neck with three different primary sites being recognized: parameningeal (PM), non-PM (NPM) and orbital (ORB). RMS of the nasopharynx represents an invasive and destructive form of the skull base. The prognosis of infiltrative form is reserved compared to that of localized forms. Treatment is mainly based on chemotherapy, radiotherapy or surgery depending on the location. We report a case of a 7yr-old child with a huge facial mass invading the skull base with a massive extension via the nasopharynx complicated by a right Orbital Apex Syndrome, the diagnosis of botryoid RMS was made and a multiple courses of chemoradiotherapy was performed with a slight improvement.

Keywords: *Rhabdomyosarcoma; Nasopharynx; Mesenchymal Cells; Children*

Introduction

Rhabdomyosarcoma (RMS) is a malignant neoplasm derived from primitive mesenchyme that retains the capacity for skeletal muscle differentiation and thus often arises at sites where striated muscle is normally absent or scanty [1]. RMS is the most common type of soft-tissue sarcoma in young children, representing 5% of all childhood malignancies [2]. By contrast, RMS occurs less frequently in adults [3]. Almost half of RMS occur in the head and neck [4,5] and three different primary sites of head and neck RMS (HNRMS) have been recognized in the following locations: parameningeal (PM), non-PM (NPM) and orbital (ORB) [6]. RMS belongs to the group of malignant undifferentiated "small round cell" tumors [7]. RMS of the nasopharynx represents an invasive and destructive form of the skull base. CT and MRI allow an accurate assessment of the tumor extension. The positive diagnosis is based on a careful pathological study completed by immunohistochemical stains as the family of small round-cell tumors is large and that is to confirm one or another diagnosis. The prognosis of infiltrative form is reserved compared to that of localized forms. Treatment is mainly based on Chemotherapy, radiotherapy or surgery depending on the location. We report a rare case of botryoid RMS of a child's nasopharynx which is rare and dangerous because of its destructive nature, anatomical complexity and management difficulty.

Case Report

A 7 years old child, presented to the ENT department with a right jugular mass, right Ptosis and Bilateral low visual acuity evolving for the last 4 months. On physical examination, a right jugular painless mass was found extending to the posterolateral part of the palate. Rhinocavoscopy under general anesthesia revealed a budding mass - bleeding on contact- protruding from the right nasal cavity and descending under the soft palate to para-pharyngeal area. Left nasal cavity was free. A biopsy through intraoral way was performed. Ophthalmologic examination found an irreversible bilateral blindness (optic atrophy) with an orbital apex syndrome of the right eye (exophthalmia + ptosis + ophthalmoplegia + diplopia + anesthesia of the upper eyelid and forehead). The rest of physical examination found no relevant abnormalities, eventually, there was no lymph node hypertrophy. Skull and face MRI (Figure 1) highlighted an extensive soft tissue process of the right side of skull base, reaching the cavernous sinus, invading the nasopharynx, the right pterygomaxillary fossa and the sphenoidal sinus, extending to the pituitary lodge -suprasellar and internal side of temporal lobe and down to the oropharynx (right tonsillar lodge). Microscopy with immunohistochemical findings were consistent with Ewing's sarcoma/PNET (anti chromogranin +, anti synaptophysin+, CD99 +, antiCD45 -, anti desmin -, anticytokeratin-).

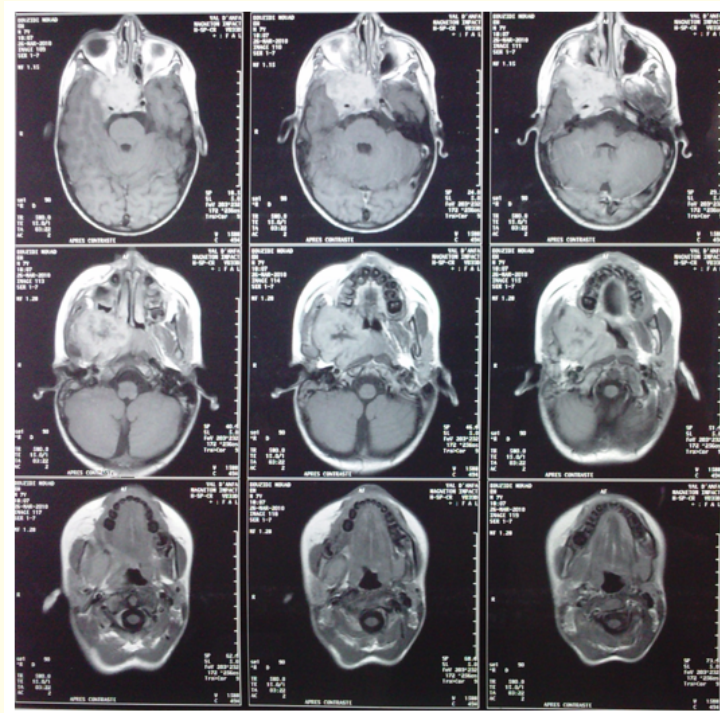


Figure 1: Skull Base MRI –Axial Section- a Soft Tissue Mass of the Right Side of the Skull Base with Extension into Deep Spaces of the Face and Intracranial Invasion.

A workup concluding chest CT, abdominal US and osteomedullary biopsy were unremarkable. The patient underwent 5 courses of chemotherapy (Vincristine, Isophosphamide, Doxorubicin and Etoposide) with fairly good clinical response, eventually the jugular mass disappeared but there were no improvement of ocular and vision disorders. On the CT scan, the volume of the tumor has clearly decreased

(Figure 2). Revisions of the slides performed at the pathology department of the University Hospital helped to straighten the diagnosis by concluding a botryoid RMS of the nasopharynx. The patient continued his chemotherapy thereafter according to the RMS 2005 high risk protocol under E group (parameningeal involvement, Tm > 5 cm). He received 5 courses of chemotherapy with persistence of the tumor on CT imaging of control. Currently, it is planned to complete the treatment with a conformational radiation therapy.

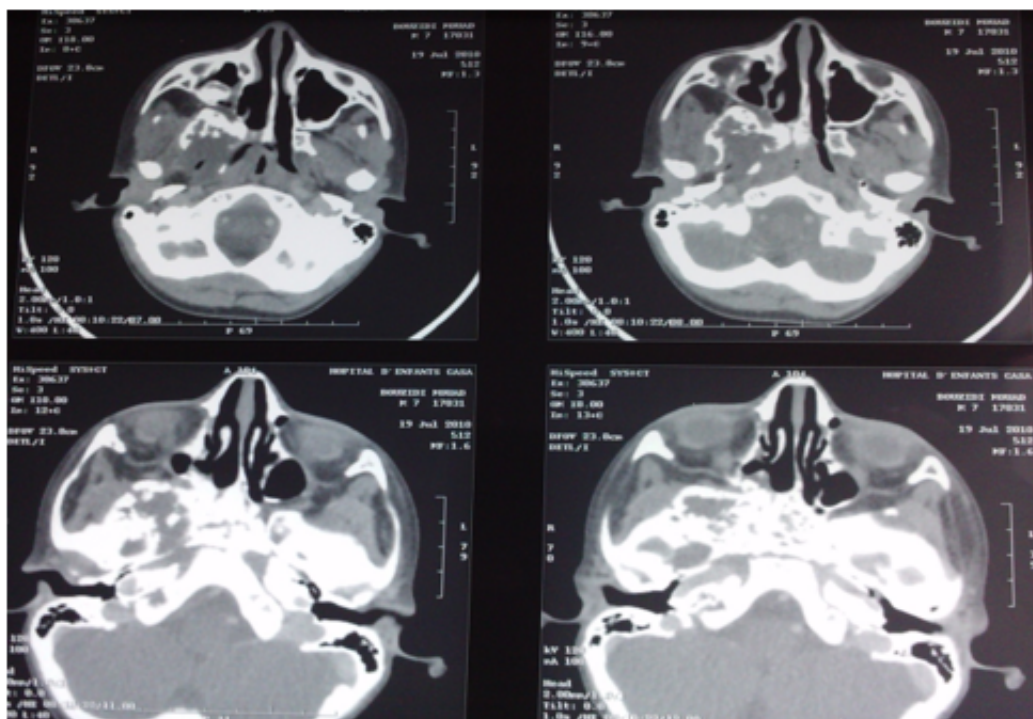


Figure 2: Cranio-Orbital CT Scan- Axial Section- (After 5 Cures of CTH): a Remarkable Reduction in Tumor Volume with an Osteolytic Tissue Process of the Skull Base at the Expense of the Body and the Great Right Wing of the sphenoid, the Clivus.

Discussion

Rhabdomyosarcoma (RMS) is a rare aggressive malignancy, commonly misdiagnosed as another type of tumor. This entity presents a high predilection for the head and neck regions with RMS in the PM, NPM and ORB locations being involved in ~50, 25 and 25% of cases, respectively [6]. It is the most common soft tissue sarcoma in children (50%) with 2/3 of cases before 6 years of age [8]. Gradually decreases with increasing age, rarely affects a person in seventh or eighth decade of life [9].

The clinical presentation is often nonspecific. It may exhibit common rhinological signs (nasal obstruction, muco-purulent rhinorrhea or epistaxis), ophthalmic signs secondary to direct extension into the orbit, or intracranial extension into the cavernous sinus (oculomotor nerve palsy with strabismus or ophthalmoplegia, decreased visual acuity, exophthalmia, papillary edema and optic atrophy), or even neurological signs due to intracranial extension in 65 to 80% of cases of parameningeal RMS that can cause headaches, papillary edema and cranial nerves palsy (VI, VII, VIII) [10]. This aggressive malignancy spreads via three routes; direct extension, lymphatic metastasis

and hematogenous metastasis. In total, $\leq 14\%$ of patients with RMS exhibit metastatic disease at presentation. (11) Lungs, lymph node and bone marrow are the common sites [1,12].

MRI accurately demonstrates the location and extent of head and neck RMS, however, this latter may exhibit certain imaging features that are similar to other tumors in the head and neck regions which makes the differential diagnosis of malignant tumors difficult when based merely on CT and MRI imaging, [13,14] therefore, the majority of masses require a biopsy to confirm the diagnosis of HNRMS. CT highlighted specifically bone involvement and the assessment of metastasis comprises thoracic CT, abdominal US, bone scintigraphy and osteomedullary biopsy.

Histopathological (H/P) diagnosis always must be confirmed by immunohistochemical investigation as the histological pattern is variable and poorly differentiated tumors bear resemblance with many other round cell malignancies including Ewing's sarcoma/PNET, non-Hodgkin lymphoma, neuroblastoma, mesenchymal chondrosarcoma, retinoblastoma (Rb), and desmoplastic small round cell tumor (DSRCT) [1].

The fourth edition of the World Health Organization (WHO) Classification of Tumors of Soft Tissue and Bone modified the classification system of RMS (International Classification of Rhabdomyosarcoma). [15,16] These changes included the elimination of botryoid RMS as an independent diagnosis, instead classifying it under typical embryonal RMS. Spindle cell/sclerosing RMS was also established as a histologic type separate from embryonal. The other 2 subtypes in the WHO system Alveolar and pleomorphic RMS were not substantially modified.

The embryonal subtype predominantly occurs in the head and neck in patients aged < 10 years and accounts for 30-80% of RMSs, which are commonly composed of spindle or botryoid cells [9,17,18]. Botryoid RMS accounts for $\sim 5\%$ of cases and is identified macroscopically by the presence of nodule-shaped polypoid masses, which are found in the mucosa-lined organs of the nasopharynx, paranasal sinus, genitourinary and gastrointestinal tracts [19]. Approximately 25% of nasopharyngeal and sinus RMS are Botryoid RMS.

Treatment of RMS is based on multimodal therapy including surgery, chemo and radiation therapy. Parameningeal RMS (nasopharynx) consists mainly of chemotherapy with conformational RTH given the critical area and the young age of the patient. Surgery is limited to biopsy given the anatomical complexity of the area, the extensive and the destructive tendency of RMS in this location.

RMS is a tumor of poor prognosis, about 30% of patients with RMS relapse, and 50% to 95% die. With regard to the functional prognosis, ocular motility can recover after treatment while the visual prognosis is much worse [20]. Prognosis of the lesion depends on age of the patient, anatomic site, clinical staging (tumor size, node involvement and metastasis) and H/P subtype [1]. Among the RMS of the head and neck, parameningeal site has the worst prognosis given its invasive and destructive nature and the tendency of skull base erosion and intracranial extension.

Classic embryonal rhabdomyosarcoma is an intermediate-risk group, 5-year survival rate is around 75% [1,6] so as botryoid RMS has a better prognosis than alveolar RMS which is classified as an unfavorable-risk group [16].

Conclusion

HNRMS is a rare and aggressive malignancy which presumptive diagnosis is based on imaging and the definitive diagnosis is mostly immunohistochemical. The survival of children with RMS has been improved through better imaging, pathological classification, the use of multi-agent chemotherapy and 3D RTH especially on parameningeal sites.

Conflict Of Interest

We declare if any financial interest or any conflict of interest exists.

Bibliography

1. Sila Datta., *et al.* "Embryonal rhabdomyosarcoma: A rare oral tumor". *Journal of Oral and Maxillofacial Pathology* 20.3 (2016): 527-531.
2. McCarville MB., *et al.* "Rhabdomyosarcoma in pediatric patients: the good, the bad, and the unusual". *American Journal of Roentgenology* 176 (2001): 1563-1569.
3. Allen SD., *et al.* "Adult rhabdomyosarcoma: cross-sectional imaging findings including histopathologic correlation". *American Journal of Roentgenology* 189 (2007): 371-377.
4. Franco A., *et al.* "Pediatric rhabdomyosarcoma at presentation: can cross-sectional imaging findings predict pathologic tumor subtype?" *European Journal of Radiology* 80 (2011): e446-e450.
5. Lloyd C and McHugh K. "The role of radiology in head and neck tumours in children". *Cancer Imaging* 10 (2010): 49-61.
6. Stevens MC., *et al.* "Treatment of nonmetastatic rhabdomyosarcoma in childhood and adolescence: third study of the International Society of Paediatric Oncology - SIOP Malignant Mesenchymal Tumor 89". *Journal of Clinical Oncology* 23 (2005): 2618-2628.
7. Saral S Desai and Nirmala A Jambhekar. "Pathology of Ewing's sarcoma/PNET: Current opinion and emerging concepts". *The Indian Journal of Orthopaedics* 44.4 (2010): 363-368.
8. Jingqi Zhu., *et al.* "Computed tomography and magnetic resonance imaging observations of rhabdomyosarcoma in the head and neck". *Oncology Letters* 8.1 (2014): 155-160.
9. Wu PX., *et al.* "Embryonal rhabdomyosarcoma of the paranasal sinuses: A case report and review of literature". *International Journal of Clinical and Experimental Medicine* 7 (2014): 2369-2372.
10. Mullaney., *et al.* "Ophthalmic Involvement as a Presenting Feature of Nonorbital Childhood Parameningeal Embryonal Rhabdomyosarcoma". *Ophthalmology* 108.1 (2001): 179-182.
11. Crist W., *et al.* "The third intergroup rhabdomyosarcoma study". *Journal of Clinical Oncology* 13 (1995): 610-630.
12. Williams BA., *et al.* "Metastatic rhabdomyosarcoma: A retrospective review of patients treated at the hospital for sick children between 1989 and 1999". *Journal of Pediatric Hematology/Oncology* 26 (2004): 243-247.
13. Holsinger FC., *et al.* "Differential diagnosis of pediatric tumors of the nasal cavity and paranasal sinuses: a 45-year multi-institutional review". *Ear, Nose and Throat Journal* 89 (2010): 534-540.
14. Saboo SS., *et al.* "Imaging features of primary and secondary adult rhabdomyosarcoma". *American Journal of Roentgenology* 199 (2012): W694-W703.
15. Newton WA., *et al.* "Classification of rhabdomyosarcomas and related sarcomas: pathologic aspects and proposal for a new classification—an intergroup rhabdomyosarcoma study". *Cancer* 76.6 (1995): 1073-1085.
16. Fletcher CDM., *et al.* "WHO Classification of Tumours of Soft Tissue and Bone. 4th ed. Lyon, France: International Agency for Research on Cancer; 2013". *World Health Organization Classification of Tumours* 5 (2013).

Citation: Merzouqi Boutaina., *et al.* "Botryoid Rhabdomyosarcoma of Nasopharynx: Case Report and Literature Review". *EC Clinical and Medical Case Reports* 4.5 (2021): 31-36.

17. Moon HS, *et al.* "A case of alveolar rhabdomyosarcoma of the ethmoid sinus invading the orbit in an adult". *Korean Journal of Ophthalmology* 20 (2006): 70-75.
18. Little DJ, *et al.* "Adult rhabdomyosarcoma: outcome following multimodality treatment". *Cancer* 95 (2002): 377-388.
19. McHugh K and Boothroyd AE. "The role of radiology in childhood rhabdomyosarcoma". *Clinical Radiology* 54 (1999): 2-10.
20. Shindler KS, *et al.* "Long-Term Follow-up and Prognosis of Orbital Apex Syndrome Resulting From Nasopharyngeal Rhabdomyosarcoma". *American Journal of Ophthalmology* 140 (2005): 236-241.

Volume 4 Issue 5 May 2021

©All rights reserved by Merzouqi Boutaina, *et al.*