

Gorlin-Goltz Syndrome: Report of 4 Cases

Amine Oualime^{1*}, Ouassime Kerdoud¹ and Faical Slimani^{1,2}

¹Faculty of Medicine and Pharmacy, Hassan 2 University of Casablanca, Morocco

²Department of Stomatology, Oral and Maxillofacial Surgery, Hospital of August 20th, University Hospital-CHU Ibn Rochd, Casablanca, Morocco

***Corresponding Author:** Amine Oualime, Faculty of Medicine and Pharmacy, Hassan 2 University of Casablanca, Morocco.

Received: August 08, 2020; **Published:** October 31, 2020

Abstract

Introduction: Gorlin-Goltz syndrome, also known as basal cell neviomatosis (CBN), is a rare inherited disorder belonging to the family of neurocristopathies or diseases caused by abnormalities of the neural ridges.

The mode of transmission is autosomal dominant with full penetrance and variable expressivity.

The diagnosis of disease is clinico-radiological, which can be confirmed by genetic study. The risk of malignant transformation of the skin lesions requires ad vitam monitoring of patients.

We report the case of 4 patients, suffering from this syndrome, followed up in the stomatology and maxillofacial surgery service in Casablanca, including a familial form in two cases: a mother and her son and 2 isolated cases, followed and treated in our service of maxillofacial surgery of the August 20 hospital in Casablanca.

A clinical, biological and radiological assessment was made followed by surgical treatment for the 3 patients, an anatomico-pathological examination and the establishment of a strict monitoring plan.

Case Report: We report the case of a 60-year-old woman and her 39-year-old son as well as a 55-year-old man, and another 36-year-old. 3 of the patients presented with multiple maxillo-mandibular cysts..

Observation 1: A 55-year-old man, with no pathological history followed in our department since November 2018, Conservative surgical treatment was performed in the patient consisting of enucleation of the cysts. Anatomical pathological examination concluded with odontogenic keratocysts.

Observation 2: A 60-year-old woman with a history of: High blood pressure under hypertensive treatment, excision of multiple maxillo-mandibular cysts in 2007, in whom clinical examination shows: a budding lesion with raised edges at the level of the lower right eyelid with extension to the free edge of the lower eyelid, a lesion in the upper left eyelid, frontal bump, diffuse café-au-lait spots on the trunk and upper limbs, surgical excision under general anesthesia with reconstruction of the lower eyelid was performed, the postoperative follow-up were favorable.

Observation 3: A 39-year-old man (the son), having as an antecedent: 1st degree consanguinity with the above-mentioned patient, on clinical examination presents: a large frontal bump, macrocephaly, diffuse pigmented lesions at the level of the face and hypertrichosis.

Observation 4: A 36-year-old man, operated at the age of seventeen for a mandibular cyst (no documents), on clinical examination presented: two swelling in the mandibular level; angular right and at the level of the left horizontal branch, an enlarged frontal bump, and two pigmentary lesions at the level of the two lower eyelids.

The diagnosis of Gorlin Goltz syndrome was made in all four patients based on various clinical and radiological criteria.

The monitoring plan is made up of regular clinical and radiological monitoring.

Discussion: Gorlin Goltz syndrome is a rare, autosomal dominant genetic disorder with variable penetrance. Its manifestations are dominated by basal cell carcinomas and multiple maxillo-mandibular odontogenic keratocysts. The course is marked by a risk of aggressive extension or recurrence of keratocysts after surgical treatment. The prognosis is conditioned by the risk of malignant transformation of the skin lesions requiring regular monitoring and systematic genetic counseling.

Keywords: *Gorlin-Goltz Syndrome; Keratocystic Odontogenic; Basocellular Nævomatosis*

Introduction

Gorlin-Goltz syndrome, also known as basal cell nevomatosis (CBN), is a rare inherited disorder belonging to the family of neurocristopathies or diseases caused by abnormalities of the neural ridges.

The mode of transmission is autosomal dominant with full penetrance and variable expressivity.

The diagnosis of disease is clinico-radiological, which can be confirmed by genetic study. The risk of malignant transformation of the skin lesions requires ad vitam monitoring of patients.

Case Report

We report the case of 4 patients, suffering from this syndrome, followed up in the stomatology and maxillofacial surgery service in Casablanca, including a familial form in two cases: a mother and her son and 2 isolated cases, followed and treated in our service of maxillofacial surgery of the August 20 hospital in Casablanca.

A clinical, biological and radiological assessment was made followed by surgical treatment for the 3 patients, an anatomic-pathological examination and the establishment of a strict monitoring plan.

Observations

We report the case of a 60-year-old woman and her 39-year-old son as well as a 55-year-old man, and another 36-year-old. 3 of the patients presented with multiple maxillo-mandibular cysts.

Observation 1: A 55-year-old man, operated on for mandibular cyst in October 2016, presented for swelling next to the ascending branch of the left mandible and the left jug, with 3 suspicious lesions in the nasal wing, the root of the left nose and the head of the left eyebrow and facial and cervical nevomatosis.

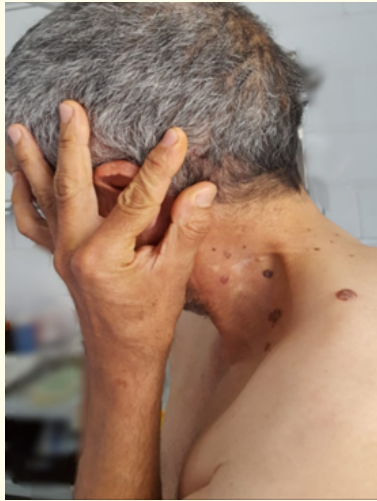

Figure 1: Cervical nevi.

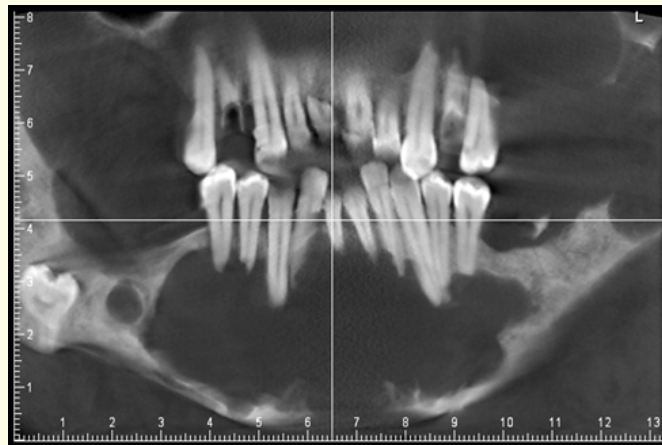


Figure 2: CT of the face showing maxillo-mandibular cysts.

Conservative surgical treatment was performed in the patient consisting of enucleation of the cysts. Anatomical pathological examination concluded with odontogenic keratocysts.

Observation 2

A 60-year-old woman with a history of: High blood pressure under hypertensive treatment, excision of multiple maxillo-mandibular cysts in 2007, in whom clinical examination shows: a budding lesion with raised edges at the level of the lower right eyelid with extension to the free edge of the lower eyelid, a lesion in the upper left eyelid, frontal bump, café-au-lait spots on the trunk and upper limbs.

A biopsy of the right palpebral lesion, the pathological examination was in favor of a nodular basal cell carcinoma and focal adenoid ulcerated. After the patient benefited from an excision of the lesions: (right internal canthal, left cheekbone, upper left eyelid, right eyelid-conjunctival) and a 2nd stage reconstruction by an advancement flap, and a graft of the oral mucosa for the conjunctival plane.

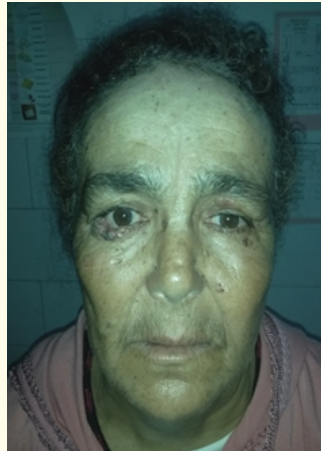

Figure 3: Nodular lesion of the right lower eyelid and the left upper eyelid.

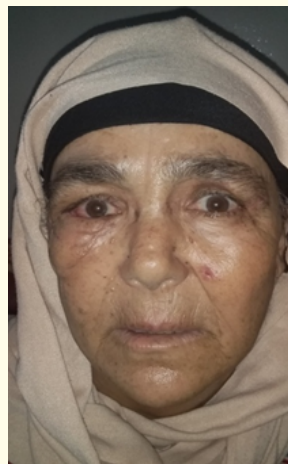

Figure 4: Picture after eyelid reconstruction (result after 1 month).

Observation 3

A 39-year-old man (the son), having as an antecedent: 1st degree consanguinity with the above-mentioned patient, on clinical examination presents: a large frontal bump, macrocephaly, diffuse pigmentary lesions at the level of the face and hypertelorism.

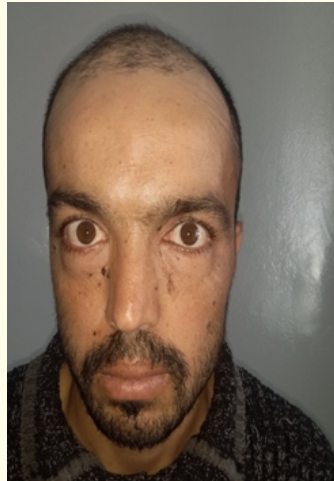


Figure 5: Facial nevi and protruding frontal bumps.

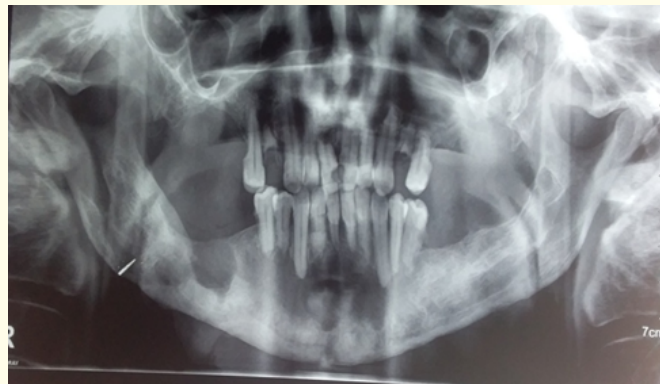

Figure 6: Mandibular cystic images.

An excision of the mandibular cyst was performed, the pathological examination was in favor of an odontogenic keratocyst.

Observation 4

A 36-year-old man, operated at the age of seventeen for a mandibular cyst (no documents), on clinical examination presented: two swelling in the mandibular level; angular right and at the level of the left horizontal branch, an enlarged frontal bump and two pigmented lesions at the level of the two lower eyelids.

The diagnosis of Gorlin Goltz syndrome was made in all four patients based on various clinical and radiological criteria.

The monitoring plan is made up of regular clinical and radiological monitoring.



Figure 7: Right cheek swelling.

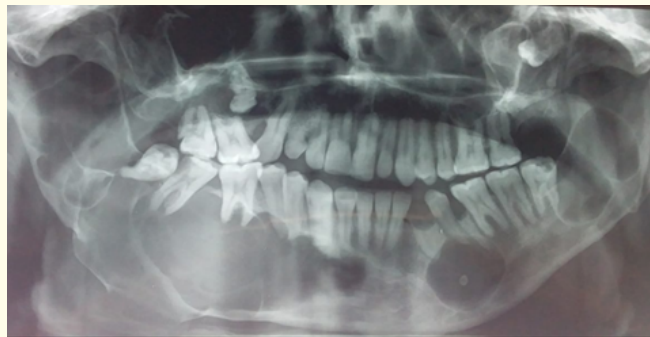

Figure 8: Tri-focal cystic image.

Discussion

Gorlin and Goltz syndrome is an autosomal dominant genetic disorder. The first description was made in 1894 by Jarisch but it was Gorlin and Goltz who in 1960 defined the affection. And since then, more than 700 cases have been reported in the literature [7].

It is a rare syndrome, its prevalence is estimated at 1/57,000 in the general population, males and females are affected in the same proportions, and the majority of cases have been reported in the Caucasian race [9].

This condition is linked to a mutation in the PTCH tumor suppressor gene having chromosomal location 9q22.3-q31 [1].

Clinically, this condition is characterized by a spectrum of developmental abnormalities and a predisposition to different cancers [3].

The first manifestations seem to be maxillary cysts, during the first decade. In a third of cases, the cutaneous signs start at puberty [3].

The clinical manifestations of Gorlin-Goltz syndrome are very diverse, we note mainly.

Maxillofacial signs

- **Odontogenic keratocysts:** Approximately 5% of keratocysts are associated with this syndrome. They are found in 80% of patients with Gorlin syndrome while they are present in only 5 to 7% of the general population, frequently discovered incidentally during a radiological assessment, for orthodontic purposes [2].
- **Dental abnormalities:** Malocclusions, impacted teeth, ectopia or heterotopia, and dental agenesis [9].

Cutaneous and mucous signs

- **Skin basal cell nevi:** Usually appear between puberty and the 3rd decade. They appear as lenticular papules a few millimeters in diameter, painless, polymorphic, single or multiple (up to several thousand), these lesions preferentially sit on the cervico-facial area as well as on the thorax [10].

The nevi can degenerate into typical basal cell epitheliomas, favored by solar exposure especially to UVB, these transformations are evidenced by an increase in size of the ridges which become crusty and ulcerated. Evolution remains local [8].

- **Palm plantar wells:** The wells found on the palms of the hands and the soles of the feet appear to be pathognomonic and are one of the major criteria for the disease [10].
- **Epidermoid cysts:** Large (1 - 2 cm) and often multiple epidermoid cysts resembling odontogenic keratocysts occur on the limbs and trunk [6].

Skeletal manifestations

- **Calcifications of the brain envelopes:** Calcifications of the scythe of the brain, the interclinoid ligaments or the tent of the cerebellum [10].
- **Anomalies in the shape of the skull:** These anomalies, although belonging to the minor criteria of the disease, are of great diagnostic interest since they are visible from birth.

The skull is unusually large with prominent frontal bumps, the eyebrow arches are prominent, hypertelorism is common [10].

- **Costal abnormalities:** Costal abnormalities are present in approximately 42% of patients with CBN, and are mainly represented by costal bifidities, agenesis, and synostosis [9].
- **Vertebral abnormalities:** Abnormalities of the cervical or thoracic vertebrae are useful diagnostic signs, being found in about 60% of affected people. The C6, C7, T1 and T2 vertebrae are most frequently involved [2].

Gynecological signs

- **Ovarian fibroids:** These fibroids are present in 25% of patients with Gorlin syndrome and are often bilateral [4].

Neurological and psychiatric signs

- Mental retardation,
- Agenesis of the corpus callosum,
- Medulloblastoma.

Diagnostic

The complexity of the clinical signs found in this syndrome has led to the establishment of specific criteria to facilitate the diagnosis. It involves finding in a patient at least two of the four major criteria or one major criterion and two minor criteria.

Diagnostic criteria for CBN
<p>Major criteria:</p> <ul style="list-style-type: none"> • Multiple basal cell carcinomas (> 2), or basal cell carcinoma before the age of 20 years • Histologically proven odontogenic cysts of the jaw • Palmoplantar pits ≥ 3 • Bifid, merged or particularly flared dimensions • Affected by a first degree relative.
<p>Minor criteria:</p> <ul style="list-style-type: none"> • Macrocephaly • Orofacial congenital malformations: cleft lip or palate, frontal lump • Hypertelorism • Radiological abnormalities: closed saddle turcica, vertebral anomalies: hemi-vertebrae, fusion or lengthening of the vertebral bodies, bone defects of the hands or feet, small flame-shaped bony gaps in the hands and feet • Ovarian fibroma • Medulloblastoma

Table

Management of patients with basal cell neviomatosis

Therapeutically, there is currently no specific treatment. Their management is symptomatic with special oncology monitoring, involving the intervention of various specialists [10].

Patients with the syndrome need information about the syndrome. The results of several epidemiological studies have shown that the risks of CBC have a strong correlation with exposure to UV radiation. Thus, these patients are able to avoid excessive exposure to the sun. It is important that they wear 100% UV blocking sunglasses since the skin around the eyes (similar to the nose/ears) is vulnerable to CBCs [8].

Sunscreens with a high protection factor (SPF 30 +) should be applied before going out and reapplied every 2 to 3 hours, and more frequently when swimming or sweating [6].

Genetic investigation is essential for the detection of new cases in the family. A neurological exam is required annually in children up to the age of seven to detect a medulloblastoma [1].

Conclusion

Gorlin and Goltz syndrome is a genetic disorder, rare, multisystem, with autosomal dominant transmission. It is classically defined by the triad composed of basal cell nevi, maxillary keratocysts and skeletal malformations. This syndrome is due to mutations in a tumor suppressor gene having 9q22.3-q31 as chromosomal location.

The carcinological potential of this syndrome is serious, justifying early detection and regular and prolonged monitoring of patients and their descendants. The treatment is simply symptomatic.

Bibliography

1. O Dereure. "Gorlin syndrome and SUFU germline mutations". *Annales de Dermatologie et de vénéréologie* 142 (2015): 231-232.
2. B Salmon., *et al.* "Odontogenic keratocyst related to a Gorlin syndrome: A case report". *Archives de Pédiatrie* 15 (2008): 406-409.
3. Mouhsine., *et al.* "Syndrome de nævomatosose baso-cellulaire: à propos de 2 cas". *Feuillets De Radiologie* 49.2 (2009): 111-115.
4. H Omrani., *et al.* "Recurrent ovarian fibromas in condition of Gorlin syndrome". *Journal de Gynécologie Obstétrique et Biologie de la Reproduction* 39 (2010): 584-587.
5. N Kadlub., *et al.* "Pediatric keratocystic odontogenic tumor and nevoid basal cell carcinoma syndrome. Predictive factors for recurrence and aggressiveness". *Revue de Stomatologie et de Chirurgie Maxillo-Faciale* 113 (2012): 148-154.
6. Kimonis VE., *et al.* "Clinical manifestations in 105 persons with nevoid basal cell carcinoma syndrome". *American Journal of Medical Genetics* 69 (1997): 229-308.
7. Ghailan MR., *et al.* "Syndrome de Gorlin-Goltz: a propos d'un cas". *Médecine Buccale, Chirurgie Buccale* 13.2 (2007): 97-101.
8. Lomuzziol. "Nevoid basal cell carcinoma syndrome (Gorlin syndrome)". *Orphanet Journal of Rare Diseases* 3 (2008): 32.
9. Manfredi M., *et al.* "Nevoid basal cell carcinoma syndrome: a review of the literature". *International Journal of Oral and Maxillofacial Surgery* 33 (2004): 117-124.
10. Lo Muzio I. "Gorlin Syndrome". *Encyclopédie Orphanet* (2002).

Volume 3 Issue 11 November 2020

All rights reserved by Amine Oualime., et al.