

Cytological and Histological Findings of an Extraskeletal Chondroma in the Temporal Region

Sana Ahuja*, Priyanka Gogoi, Preeti Diwaker and Vinod Kumar Arora

Department of Pathology, University College of Medical Sciences, New Delhi, India

***Corresponding Author:** Sana Ahuja, Department of Pathology, University College of Medical Sciences, New Delhi, India.

Received: July 01, 2019; **Published:** July 31, 2019

Abstract

Extraskeletal chondroma is a rare tumour of cartilaginous origin commonly seen in the hands and feet. It is known to arise from the soft tissues like tendon sheath and joint capsules. It is important to completely excise the tumour with intact capsule to prevent recurrence. We report a case of an extraskeletal chondroma in a 40 year female in the temporal region.

Keywords: *Chondroma; Chondrosarcoma; Chondromyxoid; Chondroid*

Introduction

Extraskeletal chondroma is a rare benign tumour arising from fibrous stroma unlike its periosteal counterpart which arises from under or in the periosteum of the cortical bone [1]. It is usually found in the hands and feet. It may arise from the joint capsules of large joints like elbow and knee [2].

Case Report

A 40-year lady presented with complaint of swelling in the right temporal region for 2 years. There was no history of any trauma. On examination, the swelling was 5 x 5 cm, hard, non-mobile, non-tender. The overlying skin was normal.

X-ray skull was suggestive of a calcified soft tissue mass in the temporal region (dermoid).

Computed tomography (Figure 1C) revealed a well defined, heterogeneously hyperdense lesion with areas of calcification in the subcutaneous plane of right temporal region with no significant post contrast enhancement. There was no evidence of any bone remodeling, erosion or destruction with no intracranial extension.

Fine needle aspiration smears from the swelling were poorly cellular with predominantly chondromyxoid stroma along with cartilaginous fragments showing chondrocytes within lacunae. Possibility of a tumour with chondroid differentiation was suggested and excision biopsy was advised for definite diagnosis (Figure 1A and 1B).

The excision specimen was a single globular encapsulated soft tissue mass measuring 5 x 4 x 4 cm. It was bony hard to cut and grey white on cross section (Figure 1D) Histological examination revealed a lobular architecture surrounded by a fibrocollagenous capsule (Figure 2A and 2B). Islands of hyaline cartilage with variable cellularity were seen. The chondrocytes showed mild atypia with absence of any mitosis, multinucleation or myxoid change (Figure 2C). There were foci of endochondral ossification, however no bony invasion was seen (Figure 2D). Based on the above histopathological findings, a final diagnosis of extraskeletal chondroma was rendered.

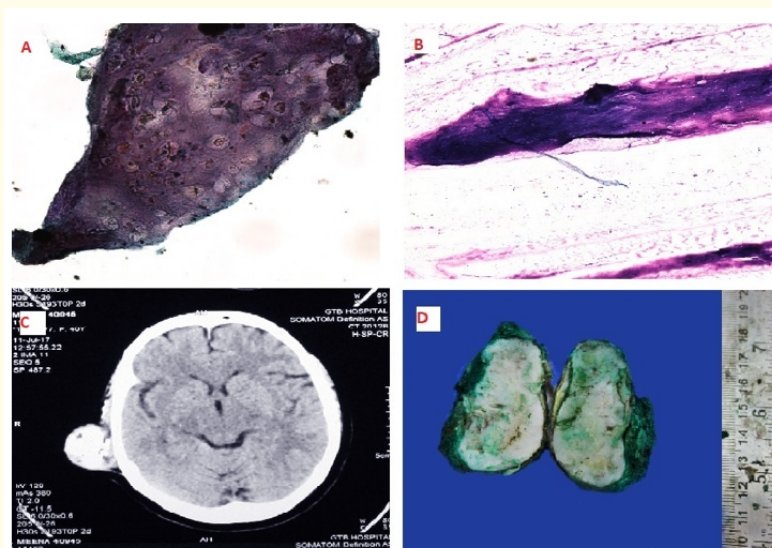


Figure 1: A: Papanicolaou stain showing cartilaginous fragment with chondrocytes. (400x magnification).
 B: May-Grünwald-Giemsa stain showing chondromyxoid stroma. (100x magnification).
 C: Computed tomography scan showing well defined hyperdense lesion with foci of calcification.
 D: Gross examination revealed a well encapsulated globular mass, grey white on cut section.

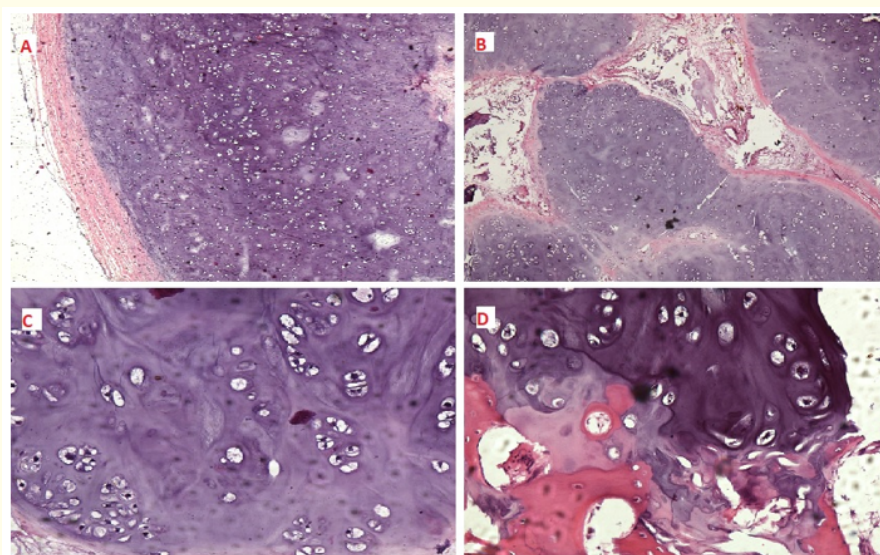


Figure 2: A and B: Hematoxylin and eosin stain showing lobular architecture with capsule. (100x magnification).
 C: Hematoxylin and eosin stain showing chondrocytes with minimal atypia in absence of necrosis. (400x magnification).
 D: Hematoxylin and eosin stain showing foci of enchondral ossification. (400x magnification).

Discussion

Extraskeletal chondromas are rare benign cartilaginous tumours seen in middle age with predisposition for males. They account for 1.5% of all benign soft tissue tumours [3]. They arise in the soft tissue near the tendon sheaths [4]. Majority of them are seen in the fingers followed by hands and feet [5,6]. Infrequent sites include dermis, subcutis, skeletal muscle, meninges and joint capsule [2]. Watanabe., *et al.* [7] and Aslam., *et al.* [8] reported a case of extraskeletal chondroma in the preauricular and parotid gland respectively, however there is no case reported in the temporal region.

Soft tissue chondromas are usually solitary, slow growing painless mass which can restrict joint mobility. They are usually painless, however pain and tenderness was reported by Chung and Enzinger in 19% of the cases [2]. Grossly they are firm, blue-white, well circumscribed and 1 - 2 cm in size. However larger tumours similar to our case have also been reported in literature [9,10].

Histological picture shows presence of a lobulated nodule surrounded by a fibrous capsule with mature hyaline cartilage. There is no association with the underlying bone. However, secondary changes like calcification, ossification, cystic change may be seen [2].

In table 1, we compared the clinicopathological parameters of our case with other studies.

Sr. No.	Names of authors	No. of cases	Site	Age (in years)	Gender	Size (in centimetres)
	Saito., <i>et al.</i> (2017) [5]	1	Index finger	63	Male	4
	Adaletli., <i>et al.</i> (2011) [11]	1	Axilla	15	Female	7
	Choi., <i>et al.</i> (2013) [12]	1	Scalp	38	Female	1
	Kim., <i>et al.</i> (2014) [6]	1	Wrist	64	Female	1.5
	Watanabe., <i>et al.</i> (2012) [7]	1	Preauricular region	43	Male	2.5
	Rajalakshmi., <i>et al.</i> (2014) [13]	1	Foot	58	Male	2
	Bahnassy., <i>et al.</i> (2009) [14]	1	Foot	42	Male	4
	Podder., <i>et al.</i> (2015) [15]	1	Index finger	26	Male	2
	Benhayoune., <i>et al.</i> (2014) [10]	2	Thigh, Iliac fossa	54, 40	Male, Male	5, 11
	Our case	1	Temporal region	40	Female	5

Table 1: Comparison of clinicopathological parameters of chondroma in various studies.

The etiology of these lesions is unclear. It is postulated that they may arise from residual embryonal tissue in a preexisting area of fetal cartilage or pluripotent mesenchymal cells which undergo metaplasia [16].

The entities included in differential diagnosis of extraskeletal chondroma include: giant cell tumour of tendon sheath, tumour calcinosis and chondrosarcoma. Giant cell tumour shows a granulomatous reaction, however no chondrocytes are seen [17]. Tumour calcinosis comes into differential when calcifications are seen in the chondroma. However, it shows foreign body giant cell reaction but no chondrocytes are seen [2].

Chondrosarcoma shows nuclear pleomorphism, multinucleation, necrosis and mitotic activity unlike its benign counterpart [2].

Treatment includes removal of the entire tumour with capsule so that no remnants are left behind to prevent recurrence as the tumour exhibits 17% risk of recurrence in case of incomplete removal [18].

Conclusion

The importance of differentiating chondroma from its malignant counterpart lies in the fact that chondroma requires only complete surgical resection while chondrosarcoma requires adjuvant therapy apart from surgical resection. The chondroma requires to be completely excised in toto with its capsule as else there is risk of recurrence from the remnants left behind [18].

Conflict of Interest

No conflict of interest.

Bibliography

1. Boriani S., *et al.* "Periosteal chondroma". *Journal of Bone and Joint Surgery* 65A.2 (1983): 205-212.
2. Chung EB and Enzinger FM. "Chondroma of soft parts". *Cancer* 41.4 (1978): 1414-1424.
3. Kransdorf M and Meis J. "Extraskeletal osseous and cartilaginous tumors of the extremities". *Radiographics* 13.4 (1993): 853-884.
4. Zhang Y and Rosenberg AE. "Cartilaginous neoplasms of soft tissue and joints". *Diagnostic Histopathology* 20.5 (2014): 200-207.
5. Saito M., *et al.* "Extraskeletal Chondroma of the Index Finger: A Case Report". *Case Reports in Oncology* 10.2 (2017): 479-484.
6. Kim OH and Kim YM. "Extraskeletal Chondroma Causing Carpal Tunnel Syndrome: A Case Report". *Journal of the Korean Society of Radiology* 70.3 (2014): 217-220.
7. Watanabe F., *et al.* "Extraskeletal Chondroma of the Preauricular Region: A Case Report and Literature Review". *Case Reports in Medicine* (2012): 121743.
8. Aslam MB and Haqqani MT. "Extraskeletal chondroma of parotid gland". *Histopathology* 48.4 (2006): 465-467.
9. Anthouli-Anagnostopoulou FA and Papachristou G. "Extraskeletal chondroma, a rare soft tissue tumor: case report". *Acta Orthopaedica Belgica* 66.4 (2000): 402-404.
10. Benhayoune K., *et al.* "Soft Tissue Chondroma: Two Cases Report and Literature Review". *Case Reports in Clinical Medicine* 3.12 (2014): 644-649.
11. Adaletli I., *et al.* "Extraskeletal chondroma: another diagnostic possibility for a soft tissue axillary mass in an adolescent". *Case Reports in Orthopedics* (2011): 309328.
12. Choi Y., *et al.* "Extraskeletal chondroma of the scalp: An atypical location". *Indian Journal of Dermatology, Venereology and Leprology* 79.3 (2013): 435-436.
13. Rajalakshmi V., *et al.* "Extraskeletal chondroma of the foot-a case report". *Journal of Clinical and Diagnostic Research* 8.3 (2014): 134-135.
14. Bahnassy M and Abdul-Khalik H. "Soft tissue chondroma: a case report and literature review". *Oman Medical Journal* 24.4 (2009): 296-299.
15. Podder D., *et al.* "Soft tissue chondroma: a rare tumor presenting as a cutaneous nodule". *Our Dermatology Online* 6.2 (2015): 173-175.
16. Yasuoka T., *et al.* "Chondroma of the tongue. Report of a case". *Journal of Maxillofacial Surgery* 12.4 (1984): 188-191.

17. Weiss SW and Goldblum JR. "Cartilaginous soft tissue tumors". In: Weiss SW, Goldblum JR, Enzinger FM, editors. *Enzinger and Weiss's soft tissue tumors*. 4th edition. St Louis: Mosby (2001): 1361-1368.
18. Dahlin DC and Salvador AH. "Cartilaginous tumors of the soft tissues of the hands and feet". *Mayo Clinic Proceedings* 49.10 (1974): 721-726.

Volume 2 Issue 5 August 2019

©All rights reserved by Sana Ahuja, et al.