

Three Cases of Androgen Insensitivity Syndrome in a Family

Tania Tofail^{1*}, Mohammad Fariduddin², Tahniyah Haq³, Shahjada Selim³, Sharmin Jahan³, Murshed Ahamed Khan⁴, Marufa Mustari⁴, Hurjahan Banu⁴ and Muhammad Abul Hasanat²

¹Resident, Department of Endocrinology, Bangabandhu Sheikh Mujib Medical University (BSMMU), Dhaka, Bangladesh

²Professor, Department of Endocrinology, Bangabandhu Sheikh Mujib Medical University (BSMMU), Dhaka, Bangladesh

³Assistant Professor, Department of Endocrinology, Bangabandhu Sheikh Mujib Medical University (BSMMU), Dhaka, Bangladesh

⁴Assistant Professor, Department of Endocrinology, Bangabandhu Sheikh Mujib Medical University (BSMMU), Dhaka, Bangladesh

***Corresponding Author:** Tania Tofail, Resident, Department of Endocrinology, Bangabandhu Sheikh Mujib Medical University (BSMMU), Dhaka, Bangladesh.

Received: June 11, 2019; **Published:** July 30, 2019

Abstract

Aims: Androgen insensitivity syndrome (AIS) is a form of 46XY Disorder of Sex Development (DSD), are rare x-linked disease, poses challenges in medical, psychological & social aspects of management. Here we present three complete androgen insensitivity syndrome (CAIS) cases from a non-consanguineous family.

Methods: We used history, clinical examination, investigations findings and management of cases.

Result: The index case (case 1) presented at 14 years of age because of under developed secondary sexual characteristics and absence of menarche. She had been reared up as female. Her tanner staging was B2, P1. There were two small ovoid masses in inguino-labial region. There was a blind vaginal pouch 2.5 cm in length. Gonads were palpable in inguino-labial region. USG failed to locate any mullerian structure. Karyotype was 46XY. Gonadotrophins and testosterone were elevated. A diagnosis of CAIS was made and manage by gonadectomy and vaginoplasty followed by hormone replacement therapy. One of her maternal cousins of 12 years (case 2) and a maternal aunt of 21 years (case 3) were found to have similar features. Their karyotype were also 46 XY. The 3rd case had history of childhood unilateral herniotomy, divorced on the ground of infertility. She had an abdominal mass which came out as gonadoblastoma-seminoma. Seminoma is a recognized complication of CAIS if the gonads are not removed at appropriate time. The External masculinization score (EMS) and Internal masculinization score (IMS) of the cases were < 11 and > 10 respectively. We may postulate for high risk infants such as female babies born to a family with CAIS history should be evaluated by EMS and IMS. Doing karyotype of babies with suspected scores (EMS < 11 and/or IMS > 10) can be a practical approach for early diagnosis and management of such diseases until we have definite molecular diagnostic facility.

Conclusion: CAIS are challenging medical, psychological & social management for physicians and a delay in proper management can result in gonadal malignancy even.

Keywords: Complete Androgen Insensitivity Syndrome; Seminoma; Gonadectomy; Disorders of Sexual Development, Testicular Germ Cell Tumour

Abbreviation

CAIS: Complete Androgen Insensitivity Syndrome; TGCT: Testicular Germ Cell Tumour; DSD: Disorder of Sexual Development; EMS: External Masculinization Score; IMS: Internal Masculinization Score

Introduction

DSDs are among the most common genetic diseases in humans referring to a group of congenital conditions in which the development of the chromosomal, gonadal or anatomical sex has been abnormal [1]. The birth of an intersex child prompts a long-term management strategy that involves a myriad of professionals working with the family. There has been progress in diagnosis, surgical techniques, understanding psychosocial issues and in recognizing and accepting the place of patient advocacy [1].

Here we report three cases of CAIS; 46XY DSD with varied clinical manifestations and different management priorities.

Cases

Case 1

The index case (case 1) presented who was reared up as a girl since birth presented at 14 years of age because primary amenorrhea and delayed puberty. At birth she had an apparent female external genitalia. She was an issue of non-consanguineous parents. Her Tanner staging was B2, P1. There were two small ovoid masses in inguinal region. There was a blind vaginal pouch 2.5 cm in length. Gonads were palpable in inguino-labial region. So, External masculinization score (EMS) was 9. Karyotype was 46XY. USG failed to locate mullerian structure. Right testis was located near the superficial inguinal ring and left one was found within labia majora. Genitogram showed there was a single opening of urethra and vagina. In none of available films contrast was seen in the vagina. Gonadotrophins and testosterone were elevated. A diagnosis of complete androgen insensitivity syndrome was made. After proper counseling patient underwent gonadectomy and vaginoplasty followed by hormone replacement therapy.

Case 2

Case 2 is another 12-year-old apparent female who is a maternal cousin of the index case presented with same complaints of primary amenorrhoea and absence of pubertal changes. Her Tanner staging was B1, P1. Two ovoid masses were present in inguinal regions. Karyotype was 46 XY. USG revealed uterus was absent. No abnormal findings are seen in adnexae. Ovaries are not identified. Well defined, hypoechoic oval homogenous structures are noted in both inguinal regions, right one is about 32 x 15 mm and left one 33 x 16 mm consistent with testes. So, External masculinization score (EMS) was 8. Hormonal evaluation showed: elevated gonadotrophins and testosterone with low estrogen. She initially underwent bilateral gonadectomy followed by vaginoplasty and started on HRT.

Case 3

Case 3 who is the maternal aunt of the earlier two cases presented with primary amenorrhoea and feeling of a lump in the abdomen for last 6 months when she is 20 years of age. There are two important points to be noted in her history. She underwent a herniotomy operation during her childhood and she had been married once which led to separation as a consequence of infertility. On examination scar mark in left inguinal region and an intra-abdominal lump, about 11x8 cm, located in right hypogastric, inguinal region, and firm in consistency, non-tender, which is mobile. So, External masculinization score (EMS) was 6.5. Tanner staging B4, P1 and no axillary hair. Karyotype and hormonal profile was like the preceding 2 cases. But MRI shows: A fairly large well defined homogeneously hyperintense mass lesion measuring about cc 9.7 cm x TD 7.18 cm x AP 7.7 cm is seen in pelvic cavity along with inguinal lymphadenopathy. Possibilities of Teratoma was the opinion from radiologist. FNAC from the lymph node revealed linear pieces of tumours composed of round to oval cells having dark central nuclei and scanty to moderate amount of cytoplasm. These cells are mostly arranged in nests surrounded by lymphocytic infiltrate with occasional histiocyte aggregates. On PAS staining, PAS positive material is demonstrated in cell cytoplasm. Later on, Histopathology of resected mass by laparotomy showed a malignant neoplasm composed of uniform large, round cells arranged in nests demarcated by fibrous septae. Cells have prominent nucleoli and clear cytoplasm. The fibrous septae contain few lymphocytes. Occasional mitoses are also seen.

Lymph node shows evidence of metastasis which was consistent with the diagnosis of seminoma.

	Test/Investigation	Case 1	Case 2	Case 3
Sex Hormone	LH	9.24 IU/L	54.14 mIU/L	42.3 mIU/L
	FSH	16.18 IU/L	164.25 IU/L	51.7 mIU/L
	Testosterone	69.54 nmol/L	29.70 nmol/L	618.5 ng/dl
	oestrogen	43 pg/ml	< 11.80 pg/ml	79.5 pg/ml
Genetic Sex	Karyotype	46XY	46XY	46XY
Mullerian structure	Ultra sonogram abdomen	Absent	Absent	Absent and a lump present.
Phenotypic Sex and body habitus		Female type with bilateral inguinolabial palpable mass and Breast stage B1	Female type with bilateral inguinolabial palpable mass and Breast stage B1.	Female type with one sided surgical scar of herniotomy and Breast stage B4.
EMS < 11		9 (Absent scrotum - 0+ Absent micophallus - 3; +Normal urethral opening- 3; +Rt. Inguino-labial gonad-1.5; + Lt. Inguino-labial gonad-1.5)	8 (Absent scrotum - 0+ Absent micophallus - 3; +Normal urethral opening- 3; +Rt. Inguinal gonad-1; + Lt. Inguinal gonad-1)	6.5 (Absent scrotum - 0+ Absent micophallus - 3; +Normal urethral opening- 3; +Rt. Gonad (hernial sac content)-0.5; + Lt. gonad abdominal 0)
IMS > 10		15	15	15
Gender Identity		Female	Female	Female

Table 1: Sex hormonal profile and other parameters of 3 DSD cases due to CAIS in a family.

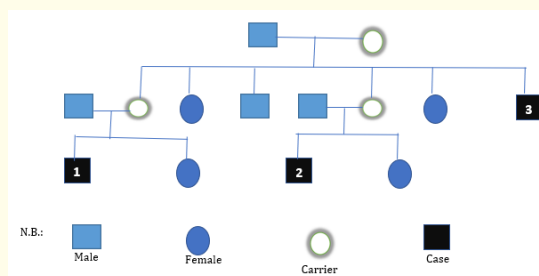


Figure 1: Pedigree chart of Case 1,2 and 3.

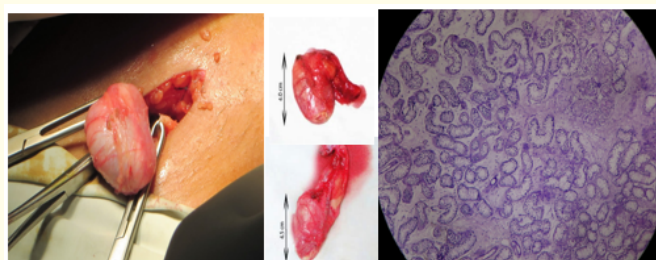
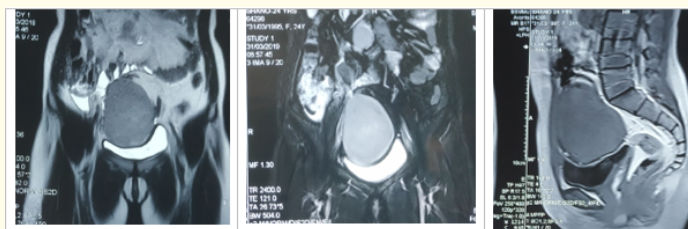
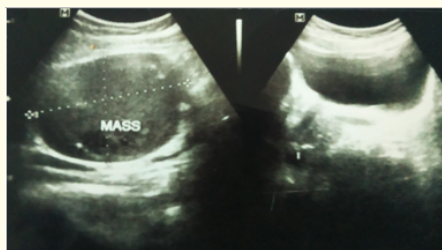


Figure 2: Surgical Anatomy and histology of a palpable gonad of case 2. The histopathology report revealed many spermatocytes with fair number of sertoli-leydig cells.



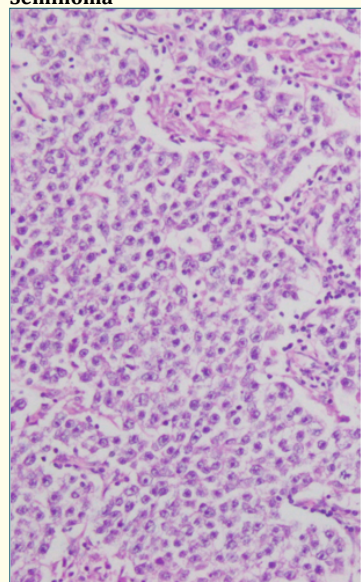
MRI Abdomen shows A fairly large well-defined oval homogeneously hyperintense mass lesion measuring about 9.7 cm x 7.18 cm x 7.7 cm is seen in pelvic cavity. Multiple enlarged lymph nodes are seen in both inguinal regions.



USG shows a large complex mass having solid cystic and few tiny calcification inside noted in right side of lower abdomen measuring about 9.8 x 7.1 cm.

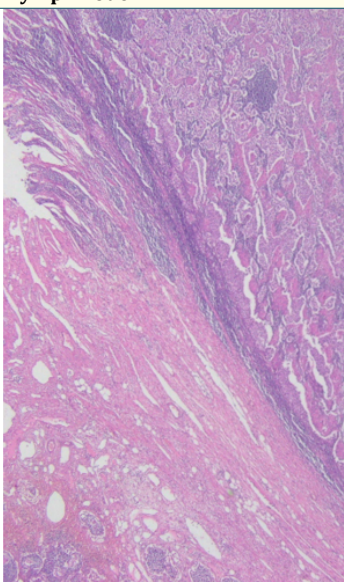
Figure 3: Imaging (MRI and Ultra sonogram) of an abdominal testis in case 3.y spermatocytes with fair number of sertoli-leydig cells.

Seminoma



Section shows a malignant neoplasm composed of uniform large, round cells arranged in nests demarcated by fibrous septae. Cells have prominent nucleoli and clear cytoplasm. The fibrous septae contain few lymphocytes. Occasional mitoses are also seen.

Lymph node



Lymph node shows evidence of metastasis.

Figure 4: Histopathology of specimen of abdominal mass.

Discussion

The androgen insensitivity syndromes (AIS) is an X-linked recessive genetic disorder which fall within the generic category of 46, XY DSD (disorder of sex development). AIS results from several mutations involving the androgen receptor (AR) gene situated in the Xq11-q12 region [2,3].

The phenotypes of an AIS case depends on the severity of resistance to the action of androgens. Accordingly, three categories are recognized: complete androgen insensitivity syndrome (CAIS), partial androgen insensitivity syndrome (PAIS), mild androgen insensitivity syndrome (MAIS). CAIS is characterized by complete feminization of the external genitalia; PAIS with a variable clinical presentation (predominantly female, predominantly male or ambiguous external genitalia); and MAIS is characterized by male external genitalia and impaired pubertal virilization [4]. Commonly a case of CAIS is detected in an adolescent female for her primary amenorrhea and less commonly in infancy for bilateral inguinal/labial swellings i.e. palpable gonads. The differential diagnosis in CAIS is limited. Our three cases are CAIS and their diagnosis were late as in our settings prenatal karyotyping is yet to be instituted. The cases 1 and 2 presented with primary amenorrhea, sexual infantilism along with inguinal mass (palpable gonads) during puberty. Their prophylactic gonadectomy were done as it has been recommended for increased risk for the development of malignant germ cell tumors [5]. Case 3 was a 21 year female with an intra-abdominal mass which turns out to be a seminoma with history of childhood unilateral herniotomy. We presume the other gonad was removed during childhood herniotomy with hernial sac content. And this is an evidence of malignant transformation of intra-abdominal male gonad and support the concept of gonadectomy' in AIS cases.

Like many areas in globe, the Genetic testing for gene mutation of CAIS is yet beyond our reach. So, we had to depend on Karyotyping and hormonal profile to make a diagnosis.

In patients with CAIS, puberty typically appears later and has a slower advance than in the general female population. However, breasts and female adiposity can develop regularly due to the action of oestradiol deriving from the peripheral aromatization of testosterone [6]. As in our cases earlier presentation in case2 had B1 stage while in case 3 it was B4. In contrast, pubic and axillary hair is absent or very rare because it mostly depends on androgen action. Likewise, all three cases had P1 stage. In regard to final height, our findings were in concert with other authors CAIS patients are typically taller than the healthy female population due to the presence of the Y chromosome, which intervenes on statural growth independently of hormonal status [4,7-10]. The typical hormone profile is characterized by a high level of luteinizing hormone (LH) above the usual reference range, while the follicle stimulating hormone (FSH) level is usually normal, probably due to gonadal inhibin regulation [11-13]. But in each of our reported cases we found FSH to be high which can be explained by continuing apoptosis of the testicular tissue leading to lack of gonadal inhibin inhibition. Moreover, the basal testosterone value results are typically within the normal male range but increased relative to the female range, while the oestradiol level is normal referring it to the male range but in the lower range for females which conforms with our findings [11,12].

There is a debate on when to perform gonadectomy in CAIS patients. Should it be postponed at least till puberty because it allows spontaneous pubertal development by oestradiol deriving from the peripheral aromatization of testosterone or it should be done as soon as the diagnosis is made due to an increased risk of testicular germ cell tumour (TGCT). In our present series one out of 3 cases developed seminoma by the age of 21 year and there is no reliable screening parameters are available to detect early (pre-) malignant changes. We will opine early gonadectomy and start of oestrogen therapy at the appropriate age for pubertal induction. Though in literature, the occurrence of TGCT in adulthood could be above 22% [14], while its incidence is very low in childhood and adolescence [15]. The most common association is reported with seminoma and gonadoblastoma, although other histological forms have been found, such as choriocarcinomas, teratomas, embryonal tumours, adenomas, and Leydig and/or Sertoli cell tumours [16,17].

For management cases of CAIS requires a holistic approach that consist proper counselling and support service; timely gonadectomy; appropriate hormone replacement therapy and assessment of the need for vaginal dilation or rarely, vaginal surgery. Awareness of high

risk population such as families with DSD and also General Physician regarding EMS, IMS, CAIS etc. may result in improve early detection, diagnosis, timely intervention and successful management. Because there is a scope of leading a near normal and socially acceptable life [18].

Conclusion

Sex assignment at or after birth should be made with caution especially in family having DSD. A female karyotype of a phenotypic female baby can exclude DSD otherwise it may be a case of bilateral cryptorchidism of DSD. A female baby with a palpable mass in inguinal or labioscrotal region should undergo prompt evaluation for DSD otherwise can result in life threatening gonadoblastoma. Early diagnosis, gonadectomy and rehabilitation are the practical means of management for DSD till today.

Acknowledgements

We acknowledge Department of Pathology, Department of Gynae-oncology for their contribution regarding management of the cases.

Conflict of Interest

The authors have declared no conflict of interest.

Bibliography

1. Hughes IA, *et al.* "Consensus Statement on Management of Intersex Disorders". *Journal of Pediatric Urology* 2.3 (2006): 148-162.
2. Lubahn D, *et al.* "Cloning of Human Androgen Receptor Complementary DNA and Localization to the X Chromosome". *Science* 240.4850 (1988): 327-330.
3. Radpour R, *et al.* "Identification of a Critical Novel Mutation in the Exon 1 of Androgen Receptor Gene in 2 Brothers With Complete Androgen Insensitivity Syndrome". *Journal of Andrology* 30.3 (2009): 230-232.
4. Papadimitriou Dimitrios T, *et al.* "Puberty in Subjects with Complete Androgen Insensitivity Syndrome". *Hormone Research in Paediatrics* 65.3 (2006): 126-131.
5. Mongan Nigel P, *et al.* "Androgen Insensitivity Syndrome". *Best Practice and Research Clinical Endocrinology and Metabolism* 29.4 (2015): 569-580.
6. Gottlieb B and Trifiro MA. "Androgen Insensitivity Syndrome". In: Adam MP, Ardinger HH, Pagon RA, *et al.*, Editors. GeneReviews® [Internet]. Seattle (WA): University of Washington, Seattle (1999): 1993-2019.
7. Ogata T and N Matsuo. "Comparison of Adult Height between Patients with XX and XY Gonadal Dysgenesis: Support for a Y Specific Growth Gene(s)". *Journal of Medical Genetics* 29.8 (1992): 539-541.
8. Zachmann Milo, *et al.* "Pubertal Growth in Patients with Androgen Insensitivity: Indirect Evidence for the Importance of Estrogens in Pubertal Growth of Girls". *The Journal of Pediatrics* 108.5 (1986): 694-697.
9. Ritzén EM. "Pubertal Growth in Genetic Disorders of Sex Hormone Action and Secretion". *Acta Paediatrica* 383 (1992): 22-26.
10. Danilovic DLS, *et al.* "Height and Bone Mineral Density in Androgen Insensitivity Syndrome with Mutations in the Androgen Receptor Gene". *Osteoporosis International* 18.3 (2007): 369-374.

11. Melo Karla FS., *et al.* "Clinical, Hormonal, Behavioral, and Genetic Characteristics of Androgen Insensitivity Syndrome in a Brazilian Cohort: Five Novel Mutations in the Androgen Receptor Gene". *The Journal of Clinical Endocrinology and Metabolism* 88.7 (2003): 3241-3250.
12. Doehnert Ulla., *et al.* "Characteristic Features of Reproductive Hormone Profiles in Late Adolescent and Adult Females with Complete Androgen Insensitivity Syndrome". *Sexual Development: Genetics, Molecular Biology, Evolution, Endocrinology, Embryology, and Pathology of Sex Determination and Differentiation* 9.2 (2015): 69-74.
13. Lahlou N., *et al.* "Intérêt Clinique Du Dosage Des Peptides Gonadiques". *Annales de Biologie Clinique* 67.3 (2009): 283-292.
14. Deans Rebecca., *et al.* "Timing of Gonadectomy in Adult Women with Complete Androgen Insensitivity Syndrome (CAIS): Patient Preferences and Clinical Evidence: Timing of Gonadectomy in Adult Women with CAIS". *Clinical Endocrinology* 76.6 (2012): 894-898.
15. Glenn Hurt W., *et al.* "Seminoma in Pubertal Patient with Androgen Insensitivity Syndrome". *American Journal of Obstetrics and Gynecology* 161.3 (1989): 530-531.
16. Kravarusic Dragan., *et al.* "Androgen Insensitivity Syndrome: Risk of Malignancy and Timing of Surgery in a Paediatric and Adolescent Population". *African Journal of Paediatric Surgery* 8.2 (2011): 194.
17. Gómez García Ignacio., *et al.* "Sertoli Cell Tumor, a Rare Testicular Tumor, Our Experience and Review of the Literature". *Archivos Espanoles De Urologia* 63.5 (2010): 392-395.
18. Ahmed SF., *et al.* "The Role of a Clinical Score in the Assessment of Ambiguous Genitalia". *BJU International* 85.1 (2000): 120-124.

Volume 2 Issue 5 August 2019

©All rights reserved by Tania Tofail, *et al.*