

Radiofrequency Ablation as Early Treatment for Extensive Chronic Radiation Proctitis or Rescue for Refractory Disease

Mohamad Suki*, Amani Beshara, Fadi Abu-baker, Baruch Ovadia, Oren Gal and Yael Kopelman

Gastroenterology and Hepatology Institute, Hillel Yaffe Medical Center, Affiliated with the Ruth and Rapaport Faculty of Medicine, The Technion, Haifa, Israel

***Corresponding Author:** Mohamad Suki, Gastroenterology and Hepatology Institute, Hillel Yaffe Medical Center, Affiliated with the Ruth and Rapaport Faculty of Medicine, The Technion, Haifa, Israel.

Received: June 26, 2019; **Published:** July 30, 2019

Abstract

Chronic radiation proctitis (CRP) is a common sequela occurring after pelvic radiotherapy, with rectal bleeding as the main presenting complaint. Radiofrequency ablation (RFA) has recently been shown to be effective in the management of CRP among other gastrointestinal pathologies. We present two cases of RFA therapy for rectal bleeding secondary to CRP. RFA was both effective and safe for control of bleeding.

Keywords: Argon Plasma Coagulation; Chronic Radiation Proctitis; Gastrointestinal Bleeding; Radiofrequency Ablation

Introduction

Chronic radiation proctitis (CRP) is a well-known cause of recurrent gastrointestinal bleeding and iron deficiency anemia. It occurs in as many as 20% of patients following pelvic radiotherapy and is believed to develop as a result of atrophy, fibrosis, and mucosal ischemia leading to obliterative endarteritis [1]. The morphology of CRP is characterized by multiple rectal telangiectasia, in many cases on the ground of friable mucosa.

Until recently, Argon plasma coagulation (APC) was the most common endoscopic therapy used, where many patients needed multiple APC sessions [2]. It is still currently recommended by the American Society for Gastrointestinal Endoscopy to be considered for superficial vascular lesions [3].

Radiofrequency ablation therapy (RFA) is a well-established treatment for several benign, premalignant, and malignant disorders. It has recently produced encouraging results in patients with a variety of gastrointestinal pathologies, including CRP [4-6]. Based on two multicenter retrospective trials [7,8], RFA appears to be a promising modality capable of providing a first- or second-line treatment option for patients with CRP, leading to complete cessation of rectal bleeding and increase in hemoglobin levels in all subjects, without major adverse events.

The aim of our case presentation was to evaluate RFA therapy for CRP patients with either extensive disease or a disease refractory to APC.

Case Presentation

We present two cases of CRP. The first case is of a 66-year-old female who presented with rectal bleeding. In the past she underwent pelvic radiotherapy for malignant neoplasm of the cervix. Laboratory testing indicated anemia requiring blood transfusions. In the first

session of sigmoidoscopy, multiple lesions of angiodysplasia were observed, some of which bled. APC therapy was performed. Further treatment with sucralfate enemas were recommended on discharge. A month later, there was a similar presentation and findings on sigmoidoscopy, and she was once again treated with APC. The third episode of rectal bleeding occurred the following month, where at this time we performed RFA therapy (Barrx™ Channel RFA Endoscopic Catheter, 15.7 x 7.5 mm, TTS 1100, 10 ablations) (Figure 1). Later, good results were obtained, clinically- with no further bleeding and with sustained hemoglobin levels (Figure 2) and better endoscopic results (Figure 3).

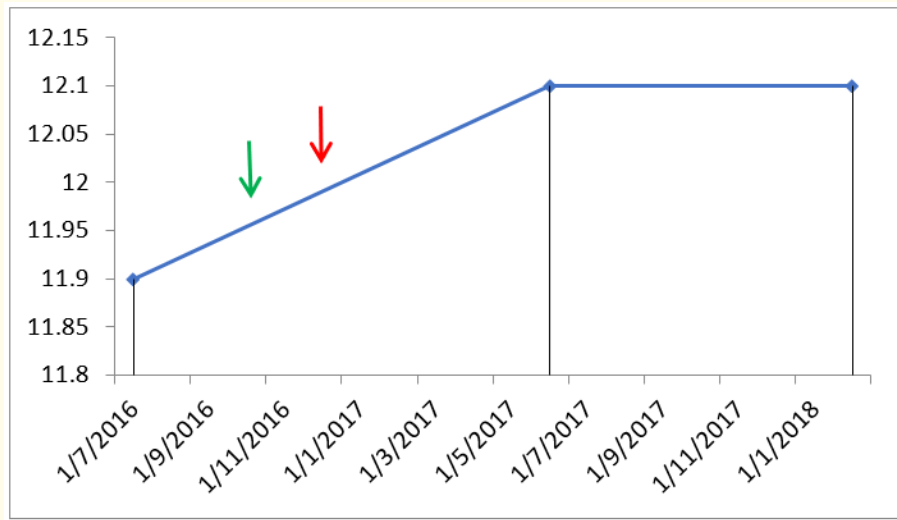


Figure 1: Hemoglobin levels. Green arrow indicates the first episode of rectal bleeding. Red arrow points indicates RFA treatment.

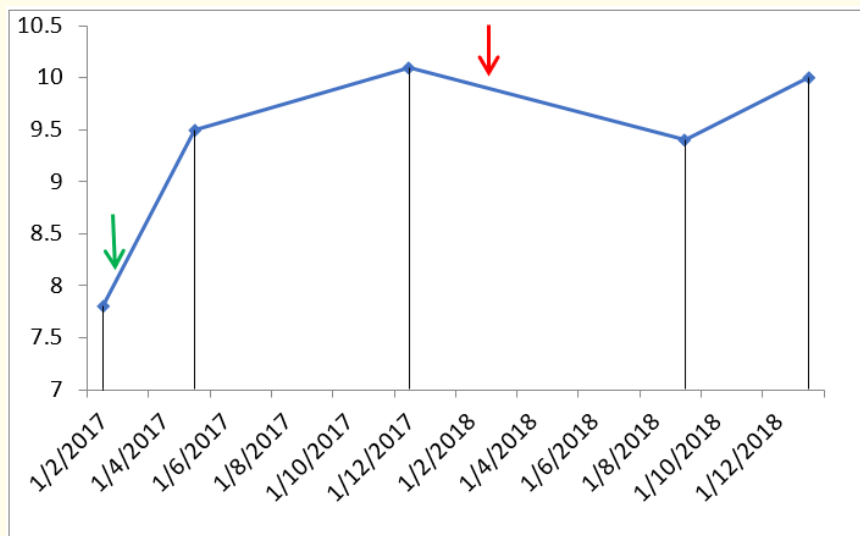


Figure 2: Hemoglobin levels. Green arrow indicates the first episode of rectal bleeding. Red arrow indicates RFA treatment.

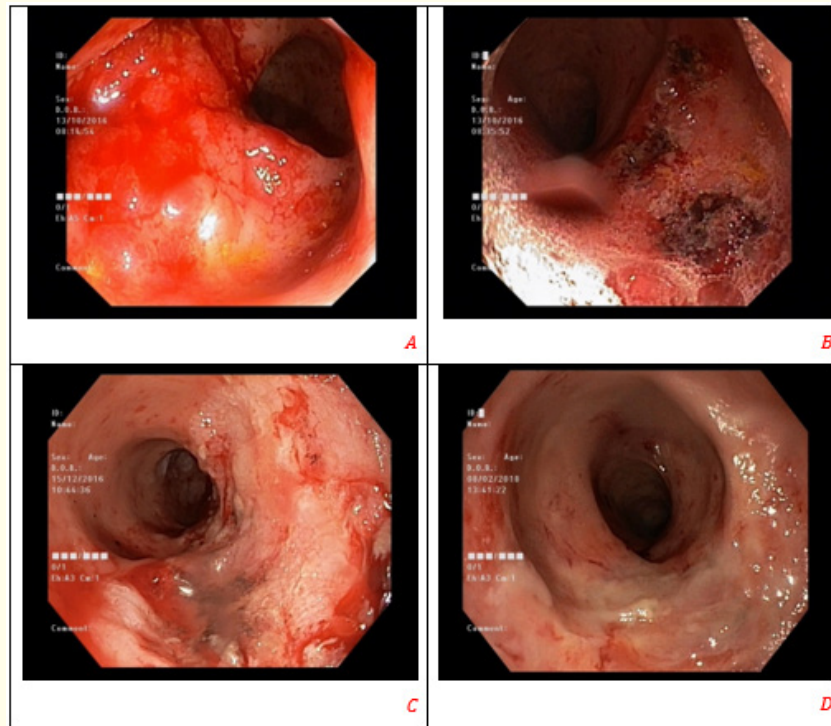


Figure 3: (A) On presentation. (B) Following first APC. (C) and (D) Following RFA.

The second case is of an 82-year-old female patient who also presented with rectal bleeding, three years following radiation therapy for rectal squamous cell carcinoma. Laboratory results are presented in figure 3. On first endoscopy, lesions of angiodysplasia were observed, and APC was performed. Due to the wide extent of disease, she was referred to an additional therapy session with RFA (12 - 15 Joule, 120 ablations), with satisfactory results. No complications were identified. During the following year no episodes of rectal bleeding were documented.

Discussion

We presented two cases where RFA was successfully performed, both in a case of APC-refractory disease or early in extensive disease. RFA treatment in both cases led to sustained hemoglobin levels as presented in figure 1 and 2. There were no further bleeding episodes, indicating a good technical success rate.

Conclusion

RFA can be safely and successfully used in both APC-refractory and extensive CP. RFA treatment for CRP led to sustained reduced bleeding episodes and sustained hemoglobin levels.

Bibliography

1. Haboubi NY, *et al.* "The light and electron microscopic features of early and late phase radiation-induced proctitis". *American Journal of Gastroenterology* 83.10 (1988): 1140-1144.

2. Rustagi T and Mashimo H. "Endoscopic management of chronic radiation proctitis". *World Journal of Gastroenterology* 17.41 (2011): 4554-4562.
3. Ginsberg GG, *et al.* "The argon plasma coagulator: February 2002". *Gastrointestinal Endoscopy* 55.7 (2002): 807-810.
4. Gross SA, *et al.* "Endoscopic mucosal ablation for the treatment of gastric antral vascular ectasia with the HALO90 system: a pilot study". *Gastrointestinal Endoscopy* 67.2 (2008): 324-327.
5. Dray X, *et al.* "Radiofrequency ablation for the treatment of gastric antral vascular ectasia". *Endoscopy* 46.11 (2014): 963-969.
6. McGorisk T, *et al.* "Radiofrequency ablation for refractory gastric antral vascular ectasia (with video)". *Gastrointestinal Endoscopy* 78.4 (2013): 584-588.
7. Rustagi T, *et al.* "Treatment of chronic radiation proctopathy with radiofrequency ablation (with video)". *Gastrointestinal Endoscopy* 81.2 (2015): 428-436.
8. Dray X, *et al.* "Radiofrequency ablation for the treatment of radiation proctitis". *Endoscopy* 46.11 (2014): 970-976.

Volume 2 Issue 5 August 2019

©All rights reserved by Mohamad Suki, *et al.*