

A Rare Complication of Totally Implantable Venous Access Port: Case Report

Alvin Lyle Kim and Seung Hun Lee*

Department of Surgery, Kosin University Gospel Hospital, Kosin University College of Medicine, Busan, Korea

***Corresponding Author:** Seung Hun Lee, Department of Surgery, Kosin University Gospel Hospital, Kosin University College of Medicine, Gamcheon-ro, Seo-gu, Busan, Korea.

Received: January 09, 2019; **Published:** April 15, 2019

Abstract

Totally implantable venous access devices (TIVADs) are useful for patients who need long term chemotherapy. Although there are many benefits, complication can also occur. We herein report a very rare case of complication who underwent TIVADs insertion. A woman who was diagnosed with intraductal carcinoma of the breast was planned to perform adjuvant chemotherapy after breast operation. Subclavian vein approached TIVADs were done. High fever occurred after 3 cycles of adjuvant chemotherapy. The patient underwent emergency foreign body removal operation. The operative findings were that the catheter was exited from the vessel and coiled around the inverted infusion port. It is named after because the shape of the coiled catheter reminds a lollipop. After the operation, the patient's laboratory test became normal and recovered successfully without postoperative complications.

Keywords: Breast; Carcinoma; Subclavian Vein; Catheter

Abbreviations

TIVADs: Totally Implantable Venous Access Devices; AJCC: American Joint Committee on Cancer

Introduction

Totally implantable venous access devices (TIVADs) have been used widely since 1980s [1]. Subcutaneous ports are used for chemotherapy because of their low rates of infection and extravasation [2]. Subcutaneous ports also have a cosmetic advantage. Despite these advantages, insertion failure or mechanical complications also occur. We herein report a very rare case of complication who underwent TIVADs insertion.

Case Report

A 50-year-old woman who was diagnosed with intraductal carcinoma of the breast from a local hospital on February 21, 2018 visited Kosin Gospel Hospital for further evaluation and treatment. The patient had a history of menarche at the age of 13 and had no other history except hysterectomy at the age of 43. The patient underwent breast conserving surgery with sentinel lymph node biopsy on February 9, 2018. Permanent pathologic result was pT2N0 based on American Joint Committee on Cancer 7th edition of cancer staging system (AJCC 7th). We planned to perform adjuvant chemotherapy, radiation therapy and hormone therapy. TIVADs insertion was done on March 5, 2018 to perform adjuvant chemotherapy. Chest plain film was taken after the procedure to see whether the device was inserted in the correct position (Figure 1). During three cycles of adjuvant chemotherapy, she was in good health. On May 2, 2018, the patient visited the emergency room with chief complaint of chilling sense and high fever. We started prophylactic antibiotic treatments. Various tests were done to find the cause of fever such as laboratory test including complete blood counts, abdominal plain film, chest plain film, urine

test, influenza test and blood culture. Neutrophil counts were slightly elevated with normal range of white blood cell counts. High fever was constantly occurring. Chest plain film was showing a strange feature (Figure 2). Patient underwent emergency foreign body removal operation. The operative findings were that the catheter was exited from the vessel and coiled around the inverted infusion port (Figure 3). On the first day after the operation, the patient’s laboratory test became normal and recovered successfully without postoperative complications.

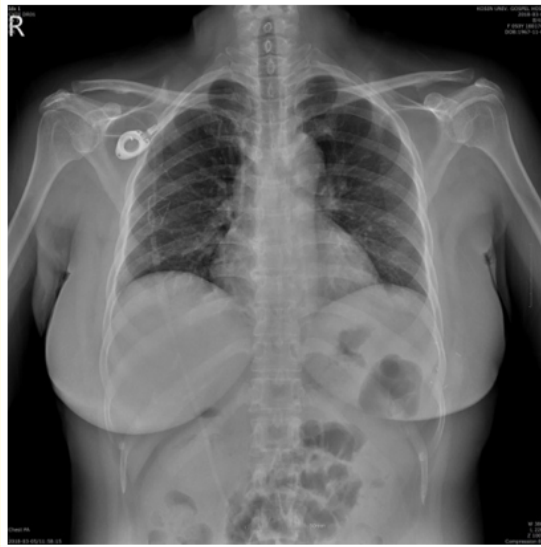

Figure 1: Confirmation of catheter tip positioning by chest radiography.

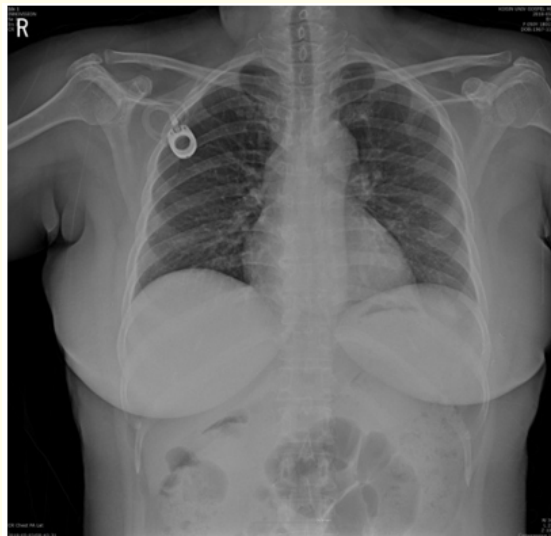


Figure 2: Chest plain film showing malpositioned catheter.

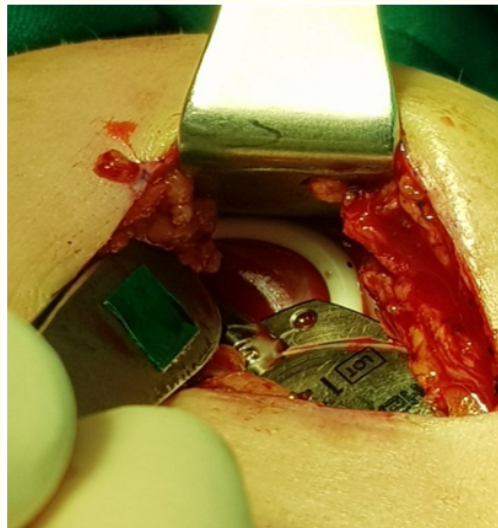


Figure 3: The infusion port was inverted and coiled catheter was seen through the subcutaneous pocket.

Discussion

Systematic reviews show minor complications of subclavian vein approached TIVADs [3]. Procedures under ultrasound guidance or site of access cannot reduce complications. Since the catheter is inserted close to the heart, complication can be fatal [4,5]. Very rare complications such as pinch off syndrome also occur [6].

This complication was named after because the shape of the coiled catheter reminds a lollipop. As far as we know, this is the first case report of Lollipop syndrome. This complication can occur when the needle is removed without pressing the skin above the infusion port. The fixed parts of the fascia surrounding the device can tear and consequently make the device move in various directions. This complication can occur more easily when undermined subcutaneous tissue pocket is created larger than the device. If the patient rotates or elevates the arm when the fixed part of the infusion port is torn, the contraction of the muscles causes the device to move in several directions, causing the catheter to be pushed out from the subclavian vein to a limited space making a loop (Figure 4).

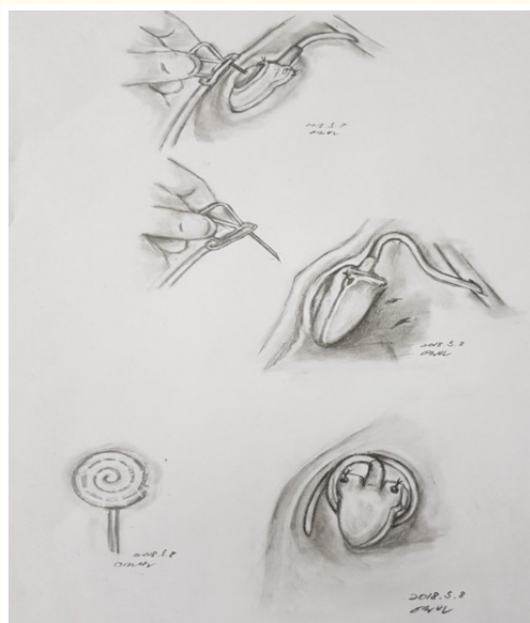


Figure 4: Illustration shows the torn fascia with detached infusion port. The infusion port moves around in a limited space and eventually catheter makes a loop which reminds a lollipop.

Conclusion

Using the device in this state, inflammatory reaction can occur. In order to prevent this complication, it is necessary to make an exact size of pocket through the subcutaneous tissues where the device is to be inserted. Placing sutures in at least three points into fascias is important to prevent device rotation. Adherence to the surrounding tissue usually takes more than 2 weeks after surgery. When removing the needle during this period, be sure to press the skin above the infusion port with one hand and then carefully remove the needle with the opposite hand.

Conflicts of Interest

The authors have no conflicts of interest.

Bibliography

1. Gyves J., *et al.* "Totally implanted system for intravenous chemotherapy in patients with cancer". *The American Journal of Medicine* 73.6 (1982): 841-845.
2. Pegues D., *et al.* "Comparison of infections in Hickman and implanted port catheters in adult solid tumor patients". *Journal of Surgical Oncology* 49.3 (1992): 156-162.
3. Arvaniti K., *et al.* "Cumulative Evidence of Randomized Controlled and Observational Studies on Catheter-Related Infection Risk of Central Venous Catheter Insertion Site in ICU Patients: A Pairwise and Network Meta-Analysis". *Critical Care Medicine* 45.4 (2017): e437-e448.
4. Bassi KK., *et al.* "Totally implantable venous access ports: retrospective review of long-term complications in 81 patients". *Indian Journal of Cancer* 49.1 (2012): 114-118.
5. Lebeaux D., *et al.* "Management of infections related to totally implantable venous-access ports: challenges and perspectives". *The Lancet Infectious Diseases* 14.2 (2014): 146-159.
6. Li H., *et al.* "Imaging evaluation of catheter integrity prevent potentially fatal complication of pinch-off syndrome: illustration of two cases". *Quantitative Imaging in Medicine and Surgery* 7.3 (2017): 369-372.

Volume 2 Issue 1 April 2019

©All rights reserved by Alvin Lyle Kim and Seung Hun Lee.