

The Metamorphosed Mesenchyme- Clear Cell sarcoma

Anubha Bajaj*

Department of Histopathology, Panjab University/A.B. Diagnostics, India

***Corresponding Author:** Anubha Bajaj, Department of Histopathology, Panjab University/A.B. Diagnostics, India.

Received: December 29, 2020; **Published:** December 30, 2020

Preface Generally, sarcomas arise from mesenchymal tissues such as muscle, adipose tissue, connective tissue, bone, vascular articulations and neural tissue. Clear cell sarcoma was initially scripted by Enzinger, *et al.* in 1965 [1]. The neoplasm is designated contingent to a component of clear cells incorporated with clear cytoplasm.

Clear cell sarcoma of soft tissue is an extremely exceptional, aggressive neoplasm engendered from neural crest cells. Clear cell sarcoma was previously denominated as malignant melanoma of soft parts. On account of morphological and immune-histochemical resemblance along with identic genetic profiling, the neoplasm is contemplated to be a genomic subtype of malignant melanoma.

The sarcoma demonstrates melanocytic differentiation on immunohistochemistry, ultrastructure and genomic assay. A predilection for preliminary regional lymph node metastasis and distant, blood-borne metastasis to sites such as pulmonary parenchyma is observed. Untreated clear cell sarcoma is progressive and manifests as widespread, fatal, metastatic disease.

Adequate discernment and confirmation of disease following onset of clinical symptoms may span several months on account of an initial contemplation as a benign neoplasm. Delay in relevant examination and cogent diagnosis may engender an advanced disease stage associated with an unfavourable prognosis.

Disease Characteristics Majority (95%) of clear cell sarcomas appear within deep-seated soft tissues of lower extremity, particularly the foot and ankle. Primary tumours may arise within upper extremity, trunk or limb girdles. Exceptionally, sites such as lumbar region, chest wall, parapharyngeal tissue, scapula, penis or neck may be incriminated. Tumefaction commonly appears adjacent to tendon sheaths, fascia and aponeuroses [2,3].

True incidence of the exceptionally discerned neoplasm remains unknown although clear cell sarcoma is anticipated to comprise of an estimated 1% of comprehensive sarcomas. The neoplasm is common in Caucasians, in contrast to African-Americans or Asians [2,3].

An equivalent gender distribution or a slight male predominance is observed [2,3].

The neoplasm is exemplified within young adults or adolescents although tumour incrimination is generally between late thirties to forties. Tumefaction can emerge between 13 years to 73 years with a mean age of disease occurrence at 25 years and median age at 39 years. Children are exceptionally implicated [2,3].

The neoplasm is gradually progressive with frequent localized tumour reoccurrence and eventual metastasis to regional lymph nodes or distant sites as the pulmonary parenchyma [2,3].

Disease Pathogenesis Precise cause, aetiology and mechanism of malignant metamorphosis remains to be elucidated. The neoplasm is predominantly of obscure genesis. Nevertheless, contingent factors proposed for malignant transformation are genetic predisposition, lymphedema, genetic mutation and adoption of chemotherapy or radiation therapy [2,3].

Genetic deformities may arise on account of certain chromosomal alterations. Thus, clear cell sarcoma is preponderantly engendered

in concurrence with specific genetic metamorphosis. In addition, pertinent risk factors associated with malignant metamorphosis are exposure to radiation and chemicals such as vinyl chloride or arsenic, chronic tissue irritation as encountered with lymphedema or foreign body implants. Majority of clear cell sarcomas are associated with a t (12;22) (q13-14; q12) genomic translocation [2,3].

Clear cell sarcoma is associated with chromosomal fusion of Ewing's sarcoma oncogene (EWS) and cellular transcription factor (ATF1) to configure the EWS/ATF1 oncogene. Tumour cells are generally diploid with only a few aneuploid cells. Aforesaid chromosomal fusion occurring due to t (12;22) (q13; q12) can be discerned with cogent cytogenetic manoeuvres such as polymerase chain reaction (PCR) and fluorescent in situ hybridization (FISH) technique in a majority (90%) of instances.

Genomic fusion between Ewing's sarcoma breakpoint region 1 (EWSR1) and camp responsive element binding protein 1 (CREB1) may also engender the neoplasm, as encountered in tumours situated within the gastrointestinal tract [2,3].

EWSR1/ ATF1 fusion protein can adequately adhere to and activate melanocyte specific microphthalmia associated transcription factor (MiTF) through SRY-related HMG-box 10 (SOX10) transcription factor. Aforesaid amalgamation initiates the expression of melanocytic phenotype, a feature which necessitates distinction from malignant melanoma [2,3].

Clinical elucidation

Comprehensive history and physical examination reveals a neoplasm which commonly appears within the lower limb, thigh or ankle as a miniature, tender nodule or swelling. Tumefaction may represent as an indolent, gradually progressive and painless mass localized beneath deep-seated soft tissue or superimposed fascia. Certain tumefaction may incriminate the subcutaneous tissue and adjacent dermis with ulceration of superimposed stratified squamous epithelium. Pattern of tumour evolution with evaluation of cogent signs and symptoms may assist preliminary tumour staging. Physical examination is mandated to assess depth and magnitude of tumefaction, adherence to adjacent anatomical structures, occurrence of oedema and neurovascular compromise [2,3].

Nearly 30% to 60% of incriminated subjects represent with pain and tenderness. Few individuals may demonstrate tumefaction associated with ulceration of superimposed epidermal layer [3,4].

Histological elucidation

Typically, the neoplasm is constituted of clear cells incorporated with intracellular glycogen. Tumour cells recapitulate histological features and immunohistochemistry of malignant melanoma [3,4].

Macroscopically, clear cell sarcoma is a solid, firm, well defined, tan or grey/white tumefaction. Tumour magnitude varies from 0.4 centimetres to 14.5 centimetres with a median dimension of 4 centimetres. A gritty sensation is observed while slicing the neoplasm. Frequent infiltration into adjacent tendons and aponeuroses is observed along with variable foci of tumour necrosis [3,4].

On fine needle aspiration cytology, smears are variably cellular and configure micro-acinar cell structures recapitulating an adenocarcinoma.

On microscopy, miniature, compact nests of uniform, neoplastic tumour cells are discerned. Tumour cell aggregates are subdivided by fibrous tissue septa into cellular clusters of variable magnitude [3,4].

The highly infiltrative neoplasm is composed of cells organized haphazardly into compact cell nests and fascicles which dissect dense, fibrous connective tissue. The cell clusters are disseminated along tendon sheaths and aponeuroses [3,4].

Neoplastic cells are imbued with abundant cytoplasm. Tumour cells are polygonal or fusiform with clear cytoplasm and a centroidal, spherical nucleus. "Clear cell" appearance of tumour cells is on account of intracellular glycogen accumulation which can be demon-

strated with periodic acid Schiff's (PAS) stain. Pigmented and non-pigmented melanosomes, disseminated multinucleated giant cells and areas of tumour necrosis are commonly observed [3,4].

Typically, tumour cells are imbued with a clear, eosinophilic cytoplasm, a centric, spherical nucleus and a basophilic nucleolus. Cytoplasm appears eosinophilic on account of accumulation of glycogen which can be highlighted with a periodic acid Schiff's (PAS) stain. Tumour cells depict minimal or absent mitosis, a feature which is in concordance with gradual tumour progression. Scattered, multinucleated giant cells may be imbued with 10 to 16 nucleoli. Disseminated foci of necrosis are observed [4,5].

Distinctive "nesting" tumour configuration is exemplified with an admixture of spindle-shaped, epithelioid and floret-like, multinucleated tumour giant cells. An estimated two thirds of tumour cells are imbued with melanin pigment. Rhabdoid cells and bizarre, pleomorphic tumour cells may be frequently enunciated along with foci of tumour necrosis. Mitotic figures are exhibited with a mean of 4 mitosis per 10 high power fields [4,5].

Majority of tumefaction exhibit a t (12;22) (q13;q12) genomic translocation with a consequent EWSR1/ATF1 genetic fusion. Aforesaid feature can aid the distinction of clear cell sarcoma from malignant melanoma.

On ultra-structural examination, tumour cells demonstrate numerous mitochondria and melanosomes [4,5].

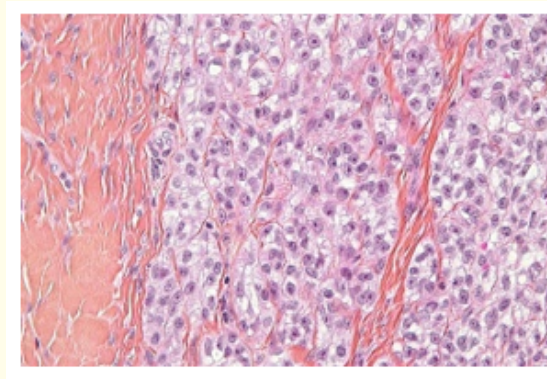


Figure 1: Clear cell sarcoma delineating nests of clear cells with clear cytoplasm, centric, spherical nucleus and occasional giant cells [9].

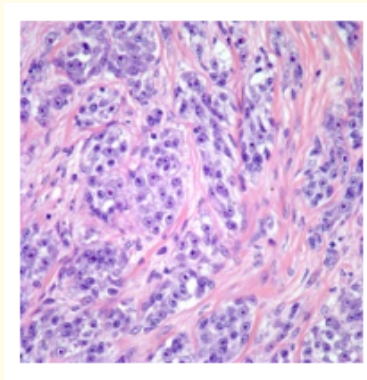


Figure 2: Clear cell sarcoma depicting fascicles of clear cells with glycogen-rich cytoplasm, spheroidal nuclei and dividing fibro-connective septa [10].

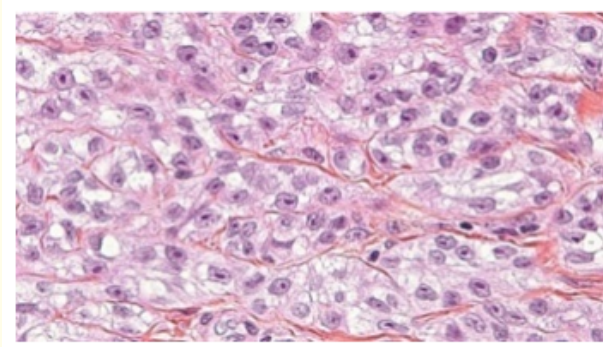


Figure 3: Clear cell sarcoma demonstrating aggregates of clear cells with central nuclei, clear cytoplasm and fibrous tissue traversing the tumour parenchyma [11].

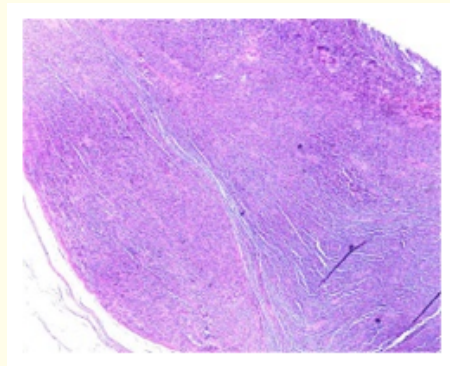


Figure 4: Clear cell sarcoma exhibiting nodules of clear cells accumulated within the subcutaneous tissue and circumscribing fibrous tissue [12].

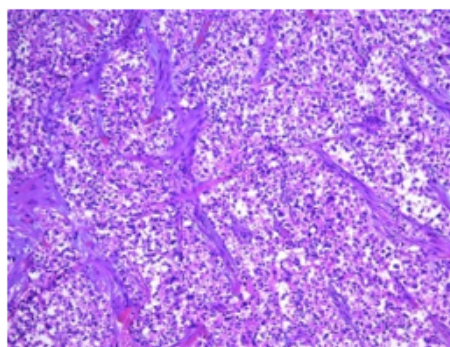


Figure 5: Clear cell sarcoma depicting nodules of clear cells with glycogen-rich cytoplasm and centric nuclei subdivided by fibrous tissue septa [13].

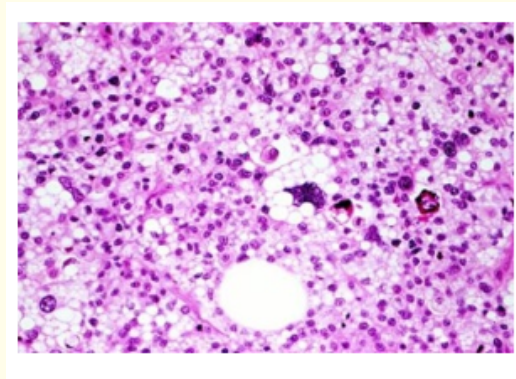


Figure 6: Clear cell sarcoma exhibiting clusters of clear cells with uniform nuclei, fibrous tissue septa and foci of tumour necrosis [14].

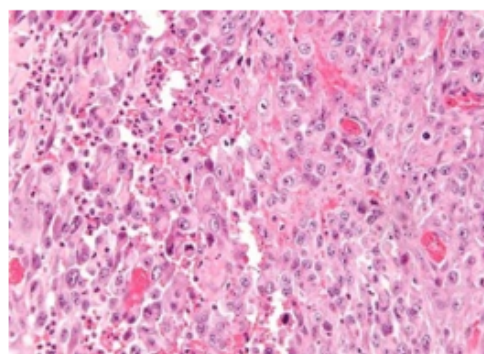


Figure 7: Clear cell sarcoma enunciating nests of clear cells with glycogen imbued cytoplasm, central nuclei, surrounding fibrous tissue and foci of tumour necrosis [14].

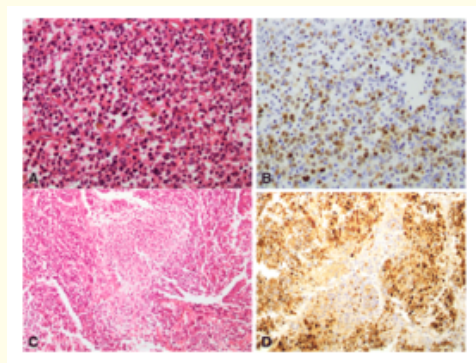


Figure 8: Clear cell sarcoma demonstrating nests of clear cells with traversing fibrous tissue septa. Immune reactive Cyclin D1 is observed [15].

Tumour Differentiation	Definition
Score 1	Sarcoma that closely resemble normal adult mesenchymal tissue
Score 2	Sarcoma for which histological typing is certain
Score 3	Embryonal and undifferentiated sarcoma, synovial sarcoma and sarcoma of uncertain differentiation
Mitotic Count	
Score 1	0-9/10 hpf
Score 2	10-19/10hpf
Score 3	≥20/10 hpf
Tumour Necrosis	
Score 0	No necrosis
Score 1	<50% tumour necrosis
Score 2	≥ 50 % tumour necrosis
Histologic grade	
Grade 1 (low grade)	Total score 2 or 3
Grade 2 (intermediate grade)	Total score 4 or 5
Grade 3 (high grade)	<50% tumour necrosis

Table 1: FNCLCC grading of clear cell soft tissue sarcoma [3].
 FNCLCC-Fédération Nationale des Centres de Lutte Contre le Cancer.

Immune histochemical elucidation

Immunohistochemistry of clear cell sarcoma recapitulates the staining pattern of malignant melanoma. Cytoplasmic and nuclear immune reactivity to antigens associated with melanin synthesis is observed such as human melanoma black 45(HMB-45) antigen, S100 protein and Melan-A. Intense immune reactivity to S100 protein, human melanoma black 45 (HMB-45) antigen, melanoma cell adhesion molecule (Melan A) and microphthalmia associated transcription factor (MiTF) is exemplified in a majority (81% to 97%) of neoplasms [5,6].

Additionally, tumour cells are immune reactive to CD99, CD57, neuron specific enolase (NSE), intracellular and extracellular iron, keratin and vimentin [5,6].

The neoplasm is immune non reactive to cytokeratin, epithelial membrane antigen(EMA), carcinoembryonic antigen (CEA), desmin, CAM5.2 and α-smooth muscle actin (α-SMA) [5,6].

Differential diagnosis

Segregation of clear cell sarcoma is required from malignant melanoma, epithelioid malignant peripheral nerve sheath tumour, cellular blue nevus, melanotic schwannoma, paraganglioma-like dermal melanocytic tumour, synovial sarcoma (monophasic type), paraganglioma, epithelioid sarcoma and diverse carcinomas [6,7].

Clear cell sarcoma situated in the proximity of tendons and aponeuroses necessitates a segregation from neoplasms such as paraganglioma-like dermal melanocytic tumour, malignant melanoma, malignant peripheral nerve sheath tumour, synovial sarcoma and clear cell melanocytic tumour [6,7].

- Primary cutaneous nodular malignant melanoma predominantly occurs in older individuals, is situated within the dermis or superficial soft tissues and incriminates the superimposed epidermal layer. Tumefaction is extensively pleomorphic and rapidly progressive. Deep-seated tendons and aponeuroses are usually spared of tumour infiltration although metastatic deposits are localized in deeper soft tissues. Additionally, t (12;22) chromosomal translocation is absent. However, a significant histological concurrence with clear cell sarcoma is observed.
- Melanotic schwannoma is an exceptional neoplasm commonly appearing in individuals with Carney's syndrome in association with spotty skin and myxomas. The neoplasm is situated within the paraspinal region or arises in concurrence with nerve plexus. Frequently, tumefaction is imbued with calcification and abundant melanin pigment [6,7].
- Synovial sarcoma commonly displays t (X;18) (p11.2;q11.2) genomic translocation which engenders SYT/SSX1 or SYT/sSSX2 genetic fusions [6,7].
- Paraganglioma -like dermal melanocytic tumour is commonly enunciated within the extremities and depicts a female predominance. Tumefaction represents as a dermal nodule with distinctive morphological features. On microscopy, tumefaction is composed of elliptical cells configuring packet-like cellular nests or groups. Enlarged epithelioid cells with enlarged nuclei and prominent nucleoli are observed. Genomic rearrangements of EWS gene are usually absent [6,7].
- Clear cell myomelanocytic tumour is a component of neoplasms designated as perivascular epithelioid cell tumour. Neoplasm is commonly represented within the abdomen, generally the ligamentum teres of hepatic viscera. Young individuals are usually incriminated [6,7].
- Malignant peripheral nerve sheath tumour is associated with enlarged peripheral nerves or neurofibromatosis. Characteristically, significant quantities of pale-staining or basophilic myxoid stroma encompasses tumour cell aggregates with hyperchromatic nuclei. Brisk mitotic activity is observed. Cytogenetic anomalies are absent. The neoplasm is immune non reactive to human melanoma black 45 (HMB-45) antigen and diverse melanocytic markers [6,7].

Investigative assay

Precise radiographic criterion for segregating malignant and benign soft tissue tumours are absent. Soft tissue sarcomas are subdivided into distinctive subtypes and necessitate the employment of diverse imaging modalities for appropriate evaluation of individual neoplasms. Adopted imaging modalities can procure a provisional diagnosis whereas a histological assessment is contemplated to be confirmatory. Plain radiography is beneficial for evaluating tumefaction arising from bone or for detecting intralesional calcification. Post operative imaging can be employed three months following culmination of therapy. High grade lesions on presentation can be subjected to imaging at 3 months to 6 months interval whereas low grade lesions are managed with annual imaging [7,8].

Conventional and accessible ultrasonography and computerized tomography (CT) may be utilized as supplementary modes of investigation in instances where magnetic resonance imaging (MRI) is contraindicated [7,8].

Computerized tomography (CT) exemplifies cogent evaluation of metastatic disease, particularly in instances of enlarged tumefaction exceeding 5 centimetre magnitude or with deep-seated neoplasms. Cross sectional, magnetic resonance imaging (MRI) is a preferential diagnostic modality for tumefaction arising from the extremities. MRI can delineate diverse muscle groups and enunciates the extent of neoplasm.

Magnetic resonance imaging (MRI) is a relevant, preliminary, superior and established methodology for assessing clear cell sarcoma, especially evaluation of primary tumour and concurrent, adjacent anatomical structures [7,8].

MRI provides clear images and spatial distribution of the neoplasm in concordance with adjacent anatomic structures such as peripheral nerves and major vascular articulations. Aforesaid manoeuvres may decimate the pre-operative morbidity and assist with superior surgical planning [7,8].

Positron emission computerized tomography (PET CT) scan may be adopted to evaluate individuals conformable to radical surgery as the neoplasm demonstrates distant haematogenous dissemination to pulmonary parenchyma or incriminates the lymphatic system [7,8].

Precise histological evaluation is necessitated for pertinent therapeutic intervention. Adequate tissue samples may be obtained with an incisional biopsy, fine needle aspiration or a core needle biopsy. Core needle biopsy is precise, preferred procedure and is associated with minimal complications. Histological evaluation of the neoplasm mandates concurrence with pertinent immunohistochemistry [7,8].

Fluorescent in situ hybridization (FISH) or reverse transcriptase polymerase chain reaction (RT-PCR) can also be adopted for accurate assessment of clear cell sarcoma and segregation from malignant melanoma [7,8].

Plain radiography of the chest and positron emission computerized tomography (PET-CT) are beneficial in excluding possible distant metastasis. Subjects on chemotherapy necessitate an evaluation for cardiac function, liver function tests and renal function tests on account of associated side effects [7,8].

Histologically low grade or grade I neoplasms are monitored at three month interval for the first postoperative year; once in four months over the next 2 years to 3 years and twice a year thereafter until the fifth postoperative year. Follow up is significant for assessment of localized tumour reoccurrence which can be adequately achieved with pertinent clinical examination and magnetic resonance imaging (MRI), especially in suspicious instances [7,8].

Individuals with high grade or grade 2 to 3 neoplasms are monitored at three month interval for a period of three years and twice a year through to the fifth year [7,8].

Prognostic outcomes

Clear cell sarcoma is associated with an inferior prognosis with overall 5 year survival percentages of 59% to 47% and 36% to 41% at 10 years. Localized tumefaction depicts an overall survival of 55% at 5 years and 41% at 10 years [2,3].

Prognostic outcomes are unfavourable on account of antecedent distant metastasis and enhanced localized tumour reoccurrence. With disease presentation, proportionate localized tumour reoccurrence is around 84% and distant metastasis at nearly 30%. Approximately 10% to 14% of subjects demonstrate regional lymph node metastasis [2,3].

Factors which significantly impact prognostic outcomes are tumour magnitude, tumour depth and cogent TNM classification. Nevertheless, tumour magnitude is a precise and cogent prognostic indicator [2,3].

Factors contributing to an unfavourable prognosis are presence of tumour necrosis, quantifiable mitotic figures, perimeter of surgical resection, anatomic location of the neoplasm and tumour magnitude. Singular factor of tumour magnitude at surgical extermination is crucial and correlates significantly with individual survival. Neoplasms exceeding 5 centimetres in dimension relapse frequently on account of micro-metastasis [2,3].

Majority or comprehensive, incriminated individuals delineate distant metastasis, frequently to pulmonary parenchyma and bones, besides exemplifying regional lymph node metastasis. The biological course of clear cell sarcoma is relentless and progressive with culmination into widespread, distant metastasis [2,3].

An appropriate preoperative imaging of clear cell sarcoma is recommended as cogent, simultaneous, surgical eradication is to be instituted as the primary curative treatment modality. Delay in adoption of optimal investigative modality and treatment strategy may culminate in an inferior prognosis [2,3].

Although overall prognosis of clear cell sarcoma is unfavourable, individuals may be disease-free following cogent therapy, display localized tumour reoccurrence or delayed distant metastasis with rapidly progressive, fatal disease. Close and extensive tumour monitoring is mandated [2,3].

Therapeutic options

Preferential treatment option for alleviating localized tumefaction is a comprehensive surgical excision with resection of wide, tumour-free perimeter. Adjuvant therapy in combination with comprehensive surgical eradication is irrelevant as significantly enhanced survival is not observed. Intralesional surgical eradication is associated with elevated proportion of localized tumour reoccurrence [7,8].

Comprehensive surgical extermination of the neoplasm with a broad, tumour-free tissue perimeter is an optimal, primary treatment strategy. Surgical eradication with removal of sufficient, circumscribing uninvolved, healthy tissue is recommended [7,8].

Radiotherapy can enhance therapeutic outcomes in individuals subjected to neoplastic eradication with close resection margins. Adjuvant, postoperative radiation therapy is employed where the recommended perimeter of 1 centimetre of healthy, tumour-free tissue is unachievable and additional surgery is improbable. Advantageous survival outcomes of adjuvant radiation therapy remain controversial [8]. Radiation therapy is advantageous in high grade (grade 2 or grade 3) neoplasms and enlarged tumefaction exceeding > 5 centimetre magnitude [7,8].

Chemotherapy is primarily employed in subjects demonstrating distant metastasis. Cisplatin-based and caffeine-assisted chemotherapy with adoption of doxorubicin or cisplatin may be beneficial in treating metastatic disease or enlarged neoplasms at presentation [7,8].

Chemotherapy is employed as a palliative treatment although efficacy of the modality is ambiguous. Anthracycline based agents display a partial effect on clear cell sarcoma with distant metastasis as the response rate is around 4%. Treatment protocols with cisplatin and ifosfamide are employed to manage stable metastatic disease. Additionally, combination of doxorubicin, dacarbazine and ifosfamide can be adopted [2,3].

An extensive disease monitoring is necessitated in order to discern localized tumour recurrence and distant metastasis [7,8].

Close monitoring is mandated following adequate surgical excision on account of enhanced proportion of localized tumour reoccurrence. Adoption of close, interval imaging is beneficial whereas annual imaging is recommended for analysing subjects with minimal tumour probability [7,8].

Bibliography

1. Enzinger FM. "Clear-Cell sarcoma of tendons and aponeuroses. An analysis of 21 cases". *Cancer* 18 (1965): 1163-1174.
2. Zamora EA and Cassaro S. "Soft tissue clear cell sarcoma". *Stat Pearls International, Treasure Island, Florida* (2020).
3. Ibrahim RM., et al. "Clear cell sarcoma- a review". *Journal of Orthopaedics* 15.4 (2018): 963-966.
4. Gonzaga MI., et al. "The epidemiology and survivorship of clear cell sarcoma: a National Cancer Database (NCDB) review". *Journal of Cancer Research and Clinical Oncology* 144.9 (2018): 1711-1716.

5. Hocar O., *et al.* "Clear cell sarcoma (malignant melanoma) of soft parts: a clinicopathologic study of 52 cases". *Dermatology Research and Practice* (2012): 984096.
6. Wang WL., *et al.* "Detection and characterization of EWSR1/ATF1 and EWSR1/CREB1 chimeric transcripts in clear cell sarcoma (melanoma of soft parts)". *Modern Pathology* 22 (2009): 1201-1209.
7. Liu C., *et al.* "Absence of 19 known hotspot oncogenic mutations in soft tissue clear cell sarcoma: two cases report with review of the literature". *International Journal of Clinical and Experimental Pathology* 7 (2014): 5242-5249.
8. Hocar O., *et al.* "Clear cell sarcoma (malignant melanoma) of soft parts: a clinicopathologic study of 52 cases". *Dermatology Research and Practice* (2012): 984096.
9. Image 1 Courtesy: Wikimedia commons.
10. Image 2 Courtesy: Wikipedia
11. Image 3 Courtesy: Science direct
12. Image 4 Courtesy: Tumour surgery.org
13. Image 5 Courtesy: Twitter
14. Image 6 and 7 Courtesy: Orthobullets.com
15. Image 8 Courtesy: Diagnostic pathology- biomed central.

Volume 4 Issue 1 January 2021

©All rights reserved by Anubha Bajaj.