

## **Antifertility Effect of Aqueous Leaf Extract of *Vernonia amygdalina* in Adult Female Wistar Rats**

**Anyanwu GE<sup>1\*</sup>, Salihu EY<sup>1</sup>, Nweze SO<sup>3</sup> and Atuadu V O<sup>2</sup>**

<sup>1</sup>Department of Anatomy, Faculty of Basic Medical Sciences, College of Medicine, University of Nigeria, Enugu Campus (UNEC), Enugu State, Nigeria

<sup>2</sup>Department of Anatomy, Faculty of Basic Medical Sciences, College of Medicine, Enugu State University of Science and Technology (ESUT), Enugu State, Nigeria

<sup>3</sup>Department of Obstetrics and Gynaecology, Parklane Teaching Hospital, Enugu State, Nigeria

**\*Corresponding Author:** Anyanwu GE, Department of Anatomy, Faculty of Basic Medical Sciences, College of Medicine, University of Nigeria, Enugu Campus (UNEC), Enugu State, Nigeria.

**Received:** December 18, 2019; **Published:** May 29, 2020

### **Abstract**

**Background:** *Vernonia amygdalina* (VA) is used in folklore medicine for birth control or in the prevention of pregnancy and for premature expulsion of fetus from the womb. This study was carried out to ascertain its possible use as female contraceptive as claimed in folklore medicine.

**Method:** Adult female wistar rats were randomly assigned into 3 groups A-C (n = 7). The animals were mated on the afternoon of proestrus phase and presence of spermatozoa (in the vaginal smear) the next morning indicated conception and day one of pregnancy. The control group A received distilled water (1 mL/kg p.o). The animals in group B and C received (100 and 200) mg/kg of extract p.o respectively from gestational day (GD) 1 to 18. Two rats from each group were randomly selected on day 10 and sacrificed. The uteri were separated and opened. The horned out sites were counted and the number of implantation sites per rat were recorded. The remaining rats were also sacrificed on day 19 of pregnancy, fetuses were removed from the pregnant rats by ventral laparotomy and fetal weight, number and the resorption sites were determined.

**Results:** The result shows that the number of the implantation sites in control group is significantly ( $P < 0.05$ ) higher than the VA treated groups. No significant difference was observed in the foetal number and foetal weights of rats in control group as compared to those in the VA treated groups. The mean progesterone level was significantly lower ( $P < 0.05$ ) in rats treated with VA as compared to the pregnant rats treated with distilled water. The histological result showed that the rats in Group B and C had severe extensive degeneration of the endometrium and loss of tissues, focal area clumping of myometrium and mild distortion of the endometrium respectively, after administration of the extract.

**Conclusion:** Results from this study support the traditional folk use of *Vernonia amygdalina* leaf as antifertility agent.

**Keywords:** *Vernonia amygdalina*; Antifertility; Progesterone; Implantation Sites and Endometrium

### **Introduction**

Contraception and fertility control (Birth control) are methods used to prevent pregnancy. Birth control is of great importance because its use in developing countries has decreased the number of maternal deaths by 40 percent and could prevent 70 percent of maternal

deaths if the full demand for birth control is met [1]. By increasing the time between pregnancies, birth control improves adult women's delivery outcomes and the survival of their children. In the developing world, women's earnings, assets, weight, and their children's schooling and health all improve with easier access to birth control [1]. Despite its many advantages, in Africa, 53 percent of women of reproductive age have an unmet need for modern contraception [2]. In most African countries, only few types of birth control are offered, which makes finding a method that fits a couple's reproductive needs difficult [2]. According to a study done by Nwachukwu and Obasi [3] in Nigeria in 2008, modern birth control methods are used by only 30 percent of respondents because most of the women rely on herbal contraception.

Herbal contraceptives and abortifacients are plants used for birth control or in the prevention of pregnancy and for premature expulsion of a fetus from the womb. In Nigeria, some women prefer this alternative means of birth control because it is cheap, accessible and constitutes little or no side effects when compared to the synthetic contraceptives and other abortion pills [3]. *Vernonia amygdalina* (bitter leaf), a member of the asteraceae family, has always been used in folk medicine as a tonic and remedy against constipation, fever, high blood pressure, and many infectious diseases [4]. It is called "Onugbu" by the Igbos of the eastern part of Nigeria who use it as vegetables [5], "Ewuro" by the Yorubas of the western part of Nigeria who use it for medicine, while the Hausas of northern Nigeria call it "Shikawa". In Nigeria, the macerated leaves of the plant are used in making soup (popularly known as ofe onugbu) while the water extract serves as a tonic drink/juice for treatment of various illnesses [6]. Recent studies reported the anti-inflammatory property of VA [7] and a crucial aspect of fertility; ovulation has been compared to an inflammatory process [8]. Thus, this study was carried out to discover the effect of VA on female fertility and its possible use as female contraceptive.

### Methodology

#### Procurement of leaves

Fresh leaves of *Vernonia amygdalina* were procured from Emene local market, Enugu. The leaves were authenticated at the Department of Botany, University of Nigeria, Nsukka, and the herbarium voucher specimen number 143c was collected.

#### Phytochemical screening

Qualitative and quantitative screening of the extract for the presence of phytochemicals were carried out at Projects Development Institute (PRODA), Enugu using conventional protocols [9].

#### Preparation of cold water extract

Fresh leaves of VA were thoroughly washed using tap water and rinsed with distilled water. The leaves were shade dried to constant weight and then pulverized to a fine powder with the aid of a Starlite blender (Model SL-999). Water was used as solvent for the preparation of the extract. Two hundred (200g) of the milled powdered leaves of VA was soaked in 400 ml of cold water in a conical flask and stirred vigorously with a glass rod for proper extraction. The combination was allowed to settle for 24 hours at room temperature. The extract was then filtered using a sieve with a tight mesh. The substrate was evaporated in an evaporator at low heat (60°C), weighed and kept in the refrigerator at 4°C.

#### Animal procurement and ethical approval

Twenty-one (21) female wistar rats (180 g) of 9 weeks old and 10 male rats (220 g) of 12 weeks old were procured from the animal house of the College of Medicine, University of Nigeria, Enugu campus and maintained in the same facility. The animals were housed in netted cages, fed with grower's mash and allowed water ad libitum. Acclimatization period of two weeks was observed. The animals were handled in strict compliance with the guidelines for animal research in National Institute of Health guidelines for care and use of laboratory animals [10].

#### Determination of estrus cycle and mating

Vaginal secretion was collected from the female rats with the aid of a plastic micropipette. Each micropipette was filled with 10 µL of formal saline (NaCl 0.9%) and inserted slightly into a rat's vagina. The vaginal fluid obtained was placed on a glass slide and the unstained

material was observed under a light microscope, without the use of the condenser lens, with 10 and 40x objective lenses. Three types of cells were recognized: round and nucleated ones which are the epithelial cells; irregular ones without nucleus which are the cornified cells; and the little round ones which are the leukocytes. The proportion of each type of cell was used for the determination of the estrous cycle phases [11].

The animals were mated on the afternoon of proestrus and the male remain in the cage until the morning of estrous. Vaginal smears were collected between 9 am - 11 am the following morning. The presence of spermatozoa (determined by microscopic examination of the vaginal smear) and vaginal plug the next morning was considered evidence of mating and indicated conception and day one of pregnancy based on the accuracy of the estrus cycle [12].

### Experimental design and administration

Adult female rats (180g) were randomly assigned to groups A-C (n = 7). Animals in group A received distilled water (10 mL/kg, p.o.) and served as normal control. The animals in groups B and C received aqueous leaf extract of VA (100 and 200 mg/kg, p.o.) from gestational day (GD) 1 to 18. Thereafter, progesterone hormonal assay and localized changes in endometrial vascular permeability, indicative of implantation were assessed at different time intervals (days 10; for implantation parameters and 18; for foetal parameter) of the pregnancy.

### Biochemical test

The hormonal analysis (Progesterone hormone) was carried out using Immunoassay (ELISA) [13]. Blood samples were collected on days 10 and 18 of pregnancy through the retro-orbital plexus into (EDTA) bottles (BD Diagnostics, Pre-analytical Systems, Midrand, USA) and allowed to clot at room temperature for 10 minutes. The samples were thereafter centrifuged at 1282g × 5 min using Hermle Bench Top Centrifuge (Model Hermle, Z300 and Hamburg, Germany). The sera were later aspirated with Pasteur pipettes into sample bottles before being analyzed for progesterone.

### Implantation and pregnancy studies; sacrifice and histological assay

The animals in Groups B and C were observed continuously at intervals of twelve (12) hours for possible abortion (bleeding) and other clinical signs after first administration following the method of Anaga [14]. Three rats from each group were randomly selected on days 10 and given 0.3 mL of 0.5% Evans blue dye via the tail vein. They were euthanized by ketamine 15 minutes later and the uteri were separated from fat and connective tissues and opened to ascertain the implantation sites as described by Bolarinwa and Olayele [15]. The horned out sites were counted and the number of uterine dye sites per rat recorded. Another 3 rats from each group were also euthanized by ketamine on day 18 of pregnancy, fetuses were removed from the pregnant rats by ventral laparotomy, and fetal weight, number and the resorption sites as well as and number of live and dead fetuses were determined [16,17]. The tissues were processed and photo-micro-graphic illustration of the H and E staining was done.

### Statistical analysis

Data were analyzed using SPSS version 22 and the values were expressed as Mean ± SD. Statistical difference in the mean was done using one-way ANOVA and Students T-test for multiple and paired variables respectively. The statistical analysis was considered significant at P < 0.05.

### Result of toxicity test

After administration of each dose, the animals were observed for twenty-four (24) hours. There was neither mortality recorded nor signs of toxicity observed in any of the rats. From the LD50 of the plant (up to 5000mg/kg), the plant is safe for human consumption.

### Result of phytochemical analysis

The quantitative phytochemical analysis of *Vernonia amygdalina* showed the amount of the different phytochemical compounds present in the leaves as shown in the tables below.

Parameter	Solvents					
	Diethyl- Ethanol	Ethyl-Acetate	Ethanol	Methanol	n-Hexane	Water
Alkaloids	+++	+++	+++	+++	+++	+++
Saponins	-	-	++	-	-	+++
Flavonoids	-	-	-	-	+	+++
Steroids	-	-	-	-	-	-
Tannins	+	-	-	+	+	+
Glycosides	-	-	++	+++	-	++
Phenols	++	+++	-	+	-	+

**Table 1:** Result of qualitative analysis of *Vernonia amygdalina*.

Where +++ is very high concentration, ++ is high concentration, + is low concentration, – is absence.

Parameters	Values	Units
Alkaloids	2.60 in 5g of sample	%
Saponins	0.35 in 20g of sample	%
Flavonoids	9.24 in 10g of sample	%
Steroids	Nil	Nil
Tannins	0.8 in 0.5g of sample	%
Glycoside	6.16 in 5g of sample	Mg/L
Phenols	3.4 in 10g of sample	%
Cyanides	0.23 in 20g of sample	Mg/L

**Table 2:** Result of quantitative analysis of *Vernonia amygdalina*.

**Result of antifertility effect of aqueous leaf extract of V.A in adult wistar rats**

Table 3 summarizes the results of VA treatment for 18 consecutive days. The extract significantly decreased implantation in treated rats. Furthermore, a significant decrease in progesterone blood levels was observed after the treatment.

Groups	No of Imp Sites	Fetal Weight (g)	Fetal No	No of Live Fetuses	No of Dead Fetuses	Fetal % Surv. Rate	Progesterone Level (µl/ml)
Group A, (normal saline)	14.7 ± 1.53	3.8 ± 13	14.00	12.0 ± 00	2.0 ± 00	85.7	90.2 ± 8.3
Group B, VA (100 mg/kg)	11.1 ± 539	3.1 ± 08	7.00	3.0 ± 00	4.0 ± 00	42.3	41.8 ± 07
Group C, VA (200mg/kg)	1.0	2.4 ± 02	3.00	1.0 ± 00	2.0 ± 00	33.3	16.0 ± 0.1
P-value	0.0294	0.067	0.861	0.615	0.087		0.004

**Table 3:** Antifertility Effect of crude leaf extract of *V. amygdalina* in adult wistar rats Data = Mean ± SEM, P < 0.05, (n = 7).

As shown in table 3, the mean number of implantation sites in the control group A was 14.7 ± 1.53 while the mean number of implantation sites in groups B and C were 11.1 ± 539 and 1.0 respectively. This shows that the number of implantation sites in the rats that were treated with *Vernonia amygdalina* was significantly lower (P < 0.05) than the number of implantation sites found in the pregnant rats that didn't receive the extract. There is significant difference between the number of the implantation site in both pregnant control rats and the VA treated rats (Table 3).

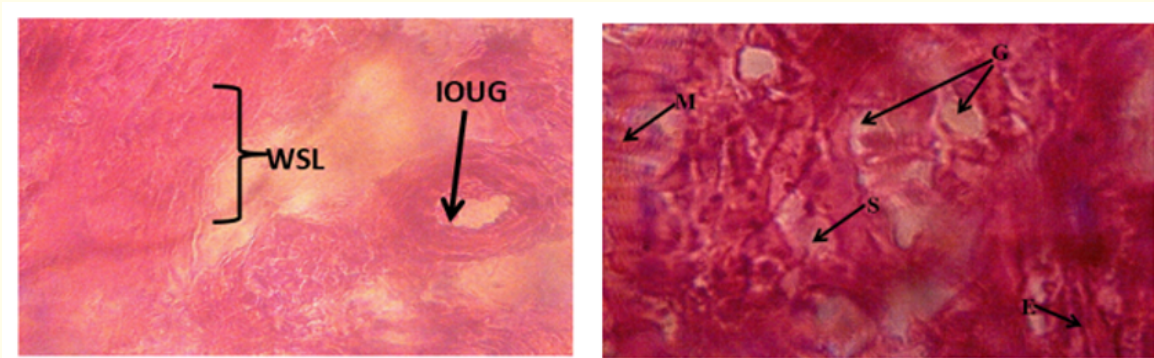
The observations on fetal condition on day 18 of pregnancy are shown in table 3. Observation of the uterus of the VA treated and control rats showed no significant difference in both the fetal number and weight. Also, the mean number of live and dead fetuses in the control group A was  $12.00 \pm 0$  and  $2.00 \pm 0$  while the mean number of live fetuses in the experimental groups B and C were  $3.00 \pm 01$  and  $4.00 \pm 0$ ;  $1.00 \pm 0$  and  $2.00 \pm 0$ . The survival percent of the Group A was 100% while the survival percentage of Groups B and C were 42.3 and 33.3%.

$$\text{Survival\%} = \frac{\text{Live fetuses} \times 100\%}{\text{Live + dead Fetuses}}$$

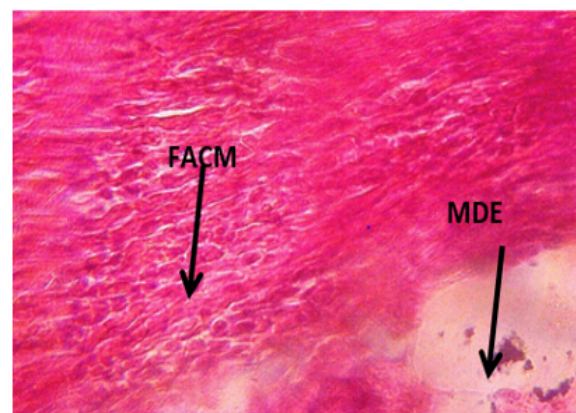
From the table 3; above, on day 18, the mean progesterone hormone level for group A was  $90.2 \pm 8.3$  while that for groups B and C were  $41 \pm 07$  and  $16.0 \pm 01$  respectively. This result shows that the progesterone hormone level of the rats that were treated with *Vernonia amygdalina* was significantly lower ( $P < 0.05$ ) than the progesterone hormone level of the pregnant rats in group a treated with distilled water.

**Histological study**

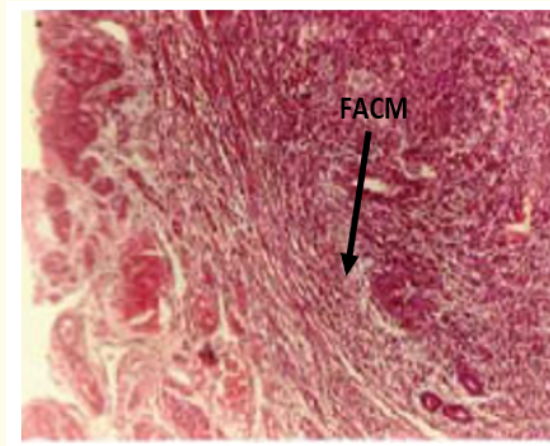
The following histological changes were observed.



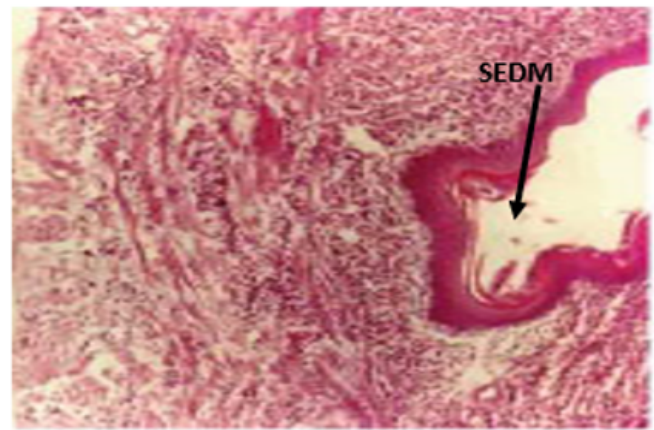
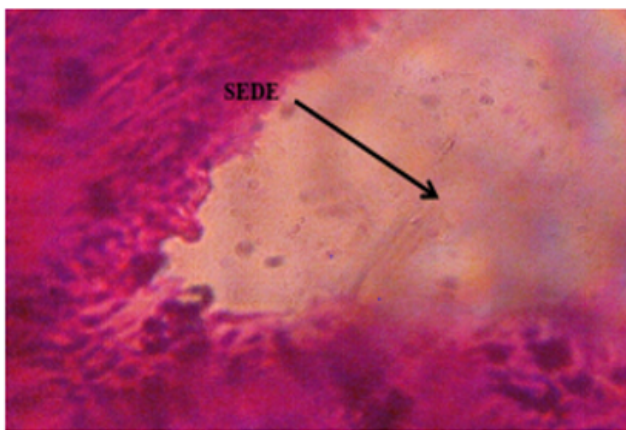
**Figure A:** Photomicrograph of uterus of Wistar rat Group A on day 9 of pregnancy showing irregular outline of uterine glands (IOUG) and widened of spongy layers (WSL), and day 18; showing normal endometrium or uterine mucosa (E), myometrium (M), uterine glands (G), and the narrow surface zone or compact zone (S). Stain used: H&E Magnification: X400 Stain used: H and E Magnification: X400.







**Figure B:** Photomicrograph of uterus of Wistar rat in Group B on days 9 and 18 of pregnancy showing focal area clumping of myometrium (FACM) and mild distortion of endometrium (MDE). H and E Magnification: X 400.



**Figure C:** Photomicrograph of uterus of Wistar rat uterus in Group C on days 9 and 18 of pregnancy, showing severe extensive degeneration of the endometrium (SEDE) and loss of tissues. H and E Magnification: X400.

### Discussion and Conclusion

The phytochemical analysis carried out in this research work revealed the presence of alkaloid, saponin, phenol, flavonoid, tannin and glycosides while steroid was absent.

In this study, the presence of alkaloids was of a higher percentage than other phytochemicals. Glycoside, phenol, flavonoid and saponins showed moderate amount whereas tannins revealed trace amount. This result is similar to previous studies conducted by [18-20].

Vaginal bleeding was observed in three (3) rats in Groups C, forty-eight hours after the first extract treatment. This result is in agreement with [21] who reported that administration of aqueous extract of the leaves of *Inula viscosa* showed abortifacient activity in rats, accompanied with vaginal bleeding in some of the rats which received the extract.

The result of the study also showed that the mean number of implantation sites in the group A was  $4.67 \pm 1.53$  while the mean number of implantation sites in the group B was 0. The mean number of implantation sites for rats that received 200mg/kg body weight of the extract was significantly ( $P < 0.05$ ) lower than those in the control group. This shows that *Vernonia amygdalina* prevents implantation. This result is in agreement with previous findings by [12,22] and showed that extract of *Vernonia amygdalina* prevents implantation and caused abortion when used in preterm pregnancy in rats.

The histological result showed normal endometrium or uterine mucosa, myometrium, uterine glands, and the narrow surface zone or compact zone in the rats in Group A, while the rats in Group B had severe extensive degeneration of the endometrium and loss of tissues. This may be attributed to the high presence of alkaloids in the extract which might have interfered with the intricate mechanism involved in the production of progesterone thereby causing degeneration of the endometrial wall and preventing implantation from taking place [23]. The endometrial wall degeneration may have been as a result of decrease in the blood levels of progesterone as progesterone has been reported to play a central role in reproduction; being involved in ovulation, implantation, and pregnancy [25]. Low levels of progesterone however, have been linked to shedding of endometrial lining. This in turn may contribute to the antifertility activity of *V. amygdalina*, such as the anti-implantation effect seen in this study (table 3). The extensive degeneration of the endometrium and loss of tissues may also be as a result of an increase in uterine contractions as *V. amygdalina* has been reported to contain a potent uterotonic agent which can be compared to that of ergometrine [24]. This is in line with a previous work by [22]. The findings from this study support the traditional use of the plant as a contraceptive in some parts of Nigeria.

Progesterone, the steroid hormone is the only naturally occurring human progestogen involved in ovulation, implantation and pregnancy. If fertilization occurs, high circulating progesterone levels are important not only for facilitating implantation, but also for maintaining pregnancy by stimulating uterine growth and opposing the actions of factors involved in myometrial contraction [24]. In this study, the mean progesterone hormone level for group A was  $90.2 \pm 8.3$  while the mean progesterone hormone levels for groups B and C given low and high doses of the extract respectively were ( $41.8 \pm 07$  and  $16.0 \pm 01$ )  $\mu\text{L}/\text{ml}$ . This result shows that the progesterone hormone level of the rats that were treated with (100 and 200) mg/kg of *Vernonia amygdalina* was significantly lower ( $P < 0.05$ ) than the progesterone hormone level of the pregnant rats in the control group A that didn't receive the extract. Therefore, *Vernonia amygdalina* has a negative impact on progesterone hormone levels. This result corresponds with a recent study by [12] on the modulatory effect of *Vernonia amygdalina* which showed that *Vernonia amygdalina* reduced the progesterone hormone significantly.

The result of the study also showed that the mean number of live and dead fetuses in the control group A were  $12.00 \pm 0$  and  $2.00 \pm 0$  respectively while the mean numbers of live and dead fetuses in the experimental groups B and C were ( $3.00 \pm 01$  and  $4.00 \pm 0$ ;  $1.00 \pm 0$  and  $2.00 \pm 0$ ) respectively. The survival percent of the Group A was 100% while the survival percentage of Groups B and C were 42.3 and 33.3%. This shows that the survival rate was highest in group A and proves that *Vernonia amygdalina* causes abortion when used in preterm pregnancy. This result is in agreement with previous findings by [12,22,25] who showed that extract of *Vernonia amygdalina* prevents implantation and caused abortion when used in preterm pregnancy in rats.

The result also showed that there was irregular outline of uterine glands (IOUG) and widened spongy layers in rats in Group A that were sacrificed on day 19 while the rats in group B showed focal area clumping of myometrium and mild distortion of the endometrium. This may also be attributed to the high presence of an uterotonic agent in the extract which stimulates and contracts the myometrium while inducing an erosion of the endometrium [24]. It is therefore safe to conclude that *Vernonia amygdalina* has antifertility potentials. As the results from this study support its traditional folklore use as an antifertility agent.

## Bibliography

1. Katz P, et al. "The economic impact of the assisted reproductive technologies". *Nature Medicine* 8.1 (2002): 29-32.
2. Assaf S, et al. "Quality of Care in Family Planning Services at Health Facilities in Senegal". DHS Analytical Studies. 55. Rockville: ICF International (2015).

3. Nwachukwu I and Obasi OO. "Use of modern birth control methods among rural communities in Imo State, Nigeria". *African Journal of Reproductive Health* 12.1 (2008): 101-108.
4. Iwu MM. "Traditional Igbo Medicine". Institute of African studies, University of Nigeria; Nsukka, Nigeria (1982): 104-110.
5. Tita RK., *et al.* "Some Properties of Medicinal Plants used by the Igbos of Nigeria". In: Traits, Tracts and Traces. Wolfgang Kreis (Ed.). Bioline International, Germany (2001): 209-210.
6. Singha SC. "Medicinal Plants of Nigeria". Nigerian National Press; Lagos, Nigeria (1965).
7. Samuel Adetunji Onasanwo., *et al.* "Anti-nociceptive and anti-inflammatory potentials of *Vernonia amygdalina* leaf extract via reductions of leucocyte migration and lipid peroxidation". *Journal of Intercultural Ethnopharmacology* 6.2 (2017): 192-198.
8. Epsy LL. "Current status of the hypothesis that mammalian ovulation is comparable to an inflammatory reaction". *Biology of Reproduction* 50 (1994): 233-238.
9. Trease GE and Evans WC. "Pharmacognosy". 11<sup>th</sup> edition. Brailliar Tiridel Can. Macmillian publishers (1989): 178-88.
10. National Institute of Health (N.I.H). "Guide for the care and use of laboratory animals". DHEW Publication. Office of Science and Health Reports; Bethesda; U.S.A. (1985).
11. Marcondes FK., *et al.* "Determination of the estrous cycle phases of rats: some helpful considerations". *Brazilian. Journal of Biology*. 62. (2002): 4.
12. Isa AI., *et al.* "The modulatory role of aqueous extract of *Vernonia amygdalina* extract on pregnant rats". *Journal of Pharmacy and Biological Sciences* 9.3. (2014): 45-47.
13. Yakubu MT., *et al.* "Effect of oral administration of aqueous extract of *Fadogia agestis* (Schweinf. Ex.Hiern) stem on some testicular function indices of male rats". *Journal of Ethnopharmacology* 115.2. (2007): 288-292.
14. Anaga AO., *et al.* "Investigation of the methanolic leaf extract of *Costus afer* Ker. for pharmacological activities *In vitro* and *In vivo*". *Phytomedicine* 11. (2004): 242-248.
15. Bolarinwa AF and Olaleye SB. "Blastocyst implantation: effect of thyroidectomy and thyroxine replacement in the rat". *African Journal of Medicine and Medical Sciences* 26.34 (1997): 135-137.
16. Kamath JV and Rana AC. "Preliminary study on antifertility activity of *Calotropis procera* roots in female rats". *Fitoterapia* 73. (2002): 111-115.
17. De Freitas TG., *et al.* "Effect of *Ruta graveolens* L. on pregnant mice". *Contraception* 71 (2005): 74-77.
18. Audu Inusa., *et al.* "Phytochemical Analysis and Antimicrobial Activity of Bitter Leaf *Vernonia amygdalina* Collected from Lapai, Niger State, Nigeria On Some Selected Pathogenic Microorganisms". *Science World Journal* 13.3 (2018): 15-18.
19. Tijjani MA., *et al.* "Phytochemical analysis, analgesic and antipyretic properties of ethanolic leaf extract of *Vernonia*". *Journal of Herbmed Pharmacology* 6. (2017): 95-99.
20. Momoh Johnson., *et al.* "Phytochemical analysis, in vitro evaluation of antioxidant and antimicrobial activity of methanolic leaf extract of *Vernonia amygdalina* (bitter leaf) against *Staphylococcus aureus* and *Pseudomonas aeruginosa*". *International Journal of Current Microbiology and Applied Science* 4 .5 (2015): 411-426.



21. Al-Dissi Nisreen M., *et al.* "Al-Hajj. Effects of *Inula viscosa* leaf extracts on abortion and implantation in rats". *Journal of Ethnopharmacology* 77 (2001): 117-121.
22. Kamatenesi-Mugisha M. "Medicinal Plants used in Reproductive Health Care in Western Uganda: Documentation, Phytochemical and Bioactivity Evaluation". PhD Thesis in Botany, Makerere University, Kampala, Uganda (2007).
23. Black, Michael H and Halmer Peter. "The encyclopedia of seeds: science, technology and uses. Wallingford, UK: CABI: (2006): 226.
24. Ijeh II., *et al.* "Effect of leaf aqueous extracts of *Vernonia amygdalina* Del on contraction of mammary gland and uterus of guinea pig dams". *American Journal of Tropical Medicine and Public Health* 1 (2011):107-116.
25. Maha Al-Asmakh. "Reproductive functions of progesterone". *Middle East Fertility Society Journal* 12.23 (2007): 147-152.
26. Chirotaw A. "*In vivo* and *In vitro* Antifertility Properties of *Vernonia amygdalina*". *Addis Ababa University School of Graduate Studies, Department of Zoology* 14 (2006).

**Volume 3 Issue 6 June 2020**

**©All rights reserved by Anyanwu GE., *et al.***