

Inbred, Connatural, Hamartoma- Nevus Sebaceous

Anubha Bajaj*

Department of Histopathology, Panjab University, A.B. Diagnostics, India

*Corresponding Author: Anubha Bajaj, Department of Histopathology, Panjab University, A.B. Diagnostics, India.

Received: April 01, 2019; Published: May 02, 2019

Abstract

Nevus sebaceous of Jadasshon is a congenital hamartoma with an epithelial and adnexal origin. The disorder is also designated as sebaceous hamartoma of Jadasshon or organoid nevus. Diverse dermal components particularly sebaceous glands, apocrine glands and hair follicles with concordant epidermal hyperplasia exemplify the lesions. Mental retardation, central nervous system defects, oculo-cardiac deformities or skeletal abnormalities appear as a clinical component of the "linear nevus sebaceous syndrome" or "Schimmelpenning syndrome". Dermoscopy is an important technique of differentiating nevus sebaceous from sebaceous hyperplasia and sebaceous adenoma. Somatic mutation of the Ras protein are encountered. Solitary, smooth, yellow tinged, well circumscribed, round to oval or linear and plaque like lesions are enunciated. Papillomatosis, hyperkeratosis, elevated quantities of sebaceous glands, absence of hair follicles and distension of apocrine glands are characteristic histological parameters. Associated neoplasm include trichilemmoma, sebaceous adenoma, desmoplastic trichilemmoma, apocrine adenoma, keratoacanthoma, leiomyoma and apocrine cystadenoma. Segregation of nevus sebaceous from conditions such as alopecia cutis congenital, mastocytoma, congenital nevi, epidermal nevus, seborrheic keratosis, verrucae and early juvenile xanthogranuloma is necessitated. Surgical excision is the mainstay for treating the congenital anomaly.

Keywords: Inbred; Connatural; Hamartoma; Nevus Sebaceous

Introduction

Nevus sebaceous of Jadasshon is a congenital anomaly initially elucidated by Josef Jadasshon in 1895. The condition, also cogitated as sebaceous hamartoma of Jadasshon or organoid nevus, is a congenital hamartoma with an epithelial and adnexal origin and is delineated in approximately 0.3% of newborns. The anomaly is comprised of divergent dermal components particularly sebaceous glands, apocrine glands and hair follicles with concordant epidermal hyperplasia. Concurrent manifestation of specific clinical attributes such as mental retardation, central nervous system defects, oculo-cardiac deformities or skeletal abnormalities cogitates the "linear nevus sebaceous syndrome" or "Schimmelpenning syndrome" which is essentially a neuro-cutaneous phakomatosis [1,2].

Disease characteristics

Nevus sebaceous is frequently enunciated on the scalp, forehead, face and neck. The lesion progresses due to hormonal modifications during puberty which induces cellular proliferation and hyperplasia thus incurring enlarged lesions with a prominently verrucous appearance. Lesions also amplify during adulthood and evolve into benign or malignant appendageal tumours with enhancing physical deformity.

Emergence of nevus sebaceous is devoid of a lack of racial and ethnic predisposition with an equivalent distribution betwixt genders. The predominantly solitary lesion either emerges at birth or at puberty. However, typical diagnostic aspects are frequently encountered at puberty.

Dermoscopy of sebaceous hamartoma is a crucial technique employed in differentiating nevus sebaceous from sebaceous hyperplasia and sebaceous adenoma, particularly when associated with degenerative alterations.

Possibility of malignant progression in nevus sebaceous is minimal, particularly in children [2,3].

Genetic associations

Nevus sebaceous does not cogitate as an inherited skin lesion. Post zygotic somatic mutation of the Ras protein family are encountered. An estimated 95% instances of nevus sebaceous enunciate an H Ras mutation and approximately 5% subjects display a K Ras mutation.

Ras mutations are frequently elucidated in secondary tumours engendered with nevus sebaceous such as trichoblastoma. On the contrary, basal cell carcinoma depicts a mutation of the hedgehog and PTCH pathway [1,3].

Clinical characteristics

Nevus sebaceous in infancy classically enunciates a smooth, velvety, yellow orange, well circumscribed plaque typically situated on the vertex of scalp although it can emerge on face and neck.

Nevus sebaceous is an asymptomatic disorder and is discerned at birth or soon thereafter. Lesions are solitary, smooth, yellow tinged, well circumscribed and round to oval or linear with a plaque like configuration. Linear articulations often disseminate along the lines of Blaschko. When arising in the scalp, nevus sebaceous is typically associated with partial or total alopecia.

Nevus sebaceous is prominent during puberty and demonstrates a verrucous or mamillated external representation on account of hormonal modifications. The particular development recapitulates histological differentiation of normal sebaceous glands of the skin.

Nevus sebaceous is a clinical diagnosis and appended investigations to further categorize the lesions are generally not required. However, a child demonstrating syndromic features of nevus sebaceous or lesions extending beyond 10 centimetres with accompanying dysfunction of central nervous system such as epilepsy or intellectual disability necessitate additional evaluation and appropriate clinical referral [3,4].

Histological characteristics

Pilosebaceous follicular unit constituting the hamartoma incorporates hair follicular, sebaceous glandular and apocrine gland configurations along with epidermal hyperplasia.

Characteristic morphological attributes comprise of papillomatosis, hyperkeratosis, amplification of quantifiable sebaceous glands, absence of hair follicles and distension of apocrine glands.

Histological attributes cogitated with primitive or childhood lesions of nevus sebaceous enunciate immature and aberrant pilosebaceous units. The superimposed epidermis delineates acanthosis and minimal papillomatosis [4,5].

Histological alterations associated with puberty incorporate enlarged lesions on clinical as well as microscopic assessment. Sebaceous glands are prominent and situated at elevated levels within the dermal region. Quantifiable sebaceous lobules and malformed ducts are augmented. Hair follicles are immature and classically depict vellus hair instead of terminal hair.

Accompanying the pubertal growth phase is extraneous epidermis which is preponderantly papillomatous and acanthotic [4,5].

Associated neoplasm

Subjects with nevus sebaceous progress to the emergence of predominantly benign and occasionally malignant tumours. Appearance of secondary tumours occurs during adulthood in an estimated 24% instances with a frequent emergence of benign basaloid proliferations such as trichoblastoma.

Secondary tumours, exclusively cogitated in adults, depict an estimated 96% of malignant tumours appearing sequentially to nevus sebaceous in individuals above 18 years and 4% subjects are betwixt 11 years to 17 years.

Secondary carcinoma arising in a nevus sebaceous is contemplated as a relatively frequent occurrence in an estimated 10% lesions. However, secondary neoplasm developing during adulthood depict a predominantly benign follicular genesis as exemplified with trichoblastoma and syringoadenoma papilliferum [5,6].

Trichoblastoma is a common neoplasm emerging in nevus sebaceous followed in frequency by syringocystadenoma papilliferum. Adjunctive accompanying neoplasm include trichilemmoma, sebaceous adenoma, desmoplastic trichilemmoma, apocrine adenoma, keratoacanthoma, leiomyoma and apocrine cystadenoma.

Malignant transformation in nevus sebaceous is cogitated in 0% to 22% individuals with an mean prevalence of 8%. Basal cell carcinoma is predominantly enunciated although a misdiagnosed trichoblastoma, which recapitulates the histology of basal cell carcinoma, enhances the percentage of quantifiable malignant neoplasm. Besides a basal cell carcinoma, malignant transformation to an eccrine poroma can ensue. Malignant neoplasm delineated with nevus sebaceous are generally metastatic when discerned.

Attributes such as sudden alteration in colour, texture or magnitude of lesions raise a suspicion of malignant conversion [6,7].

Differential diagnosis

Demarcation of nevus sebaceous from adjunctive neoplasm is contingent to stage of development of the lesion. In infants, distinction of nevus sebaceous from alopecia cutis congenita or mastocytoma is a pre-requisite.

In late childhood or adults, distinction of nevus sebaceous from conditions such as congenital nevi, epidermal nevus, seborrheic keratosis, verrucae and early juvenile xanthogranuloma is necessitated [7,8].

Therapeutic indications

Clinical appearance and cosmetic disfigurement indicate the necessity of therapeutic removal of nevus sebaceous.

Surgical excision is the mainstay for appropriately treating the congenital anomaly. However, optimal and scheduled eradication of nevus sebaceous remains a debatable entity.

Nevus sebaceous was previously considered as a lesion with an augmented risk of malignant transformation. Secondary carcinoma possibly developed in adulthood and a prophylactic surgical excision was an appropriate option [8,9].

However, the currently anticipated probability of a progressive secondary carcinoma is minimal whereas secondary benign neoplasm are frequently encountered.

Specific benign neoplasm associated with nevus sebaceous include syringocystadenoma papilliferum and trichoblastoma. Thus, surgical eradication of the lesion is contemplated as a suitable therapy during early teens with minimal anaesthesia induced complications.

Majority of secondary malignancies arising in a nevus sebaceous appear at 40 years of age or above.

Cosmetic considerations for removing nevus sebaceous appear on account of enlarged, verrucous facial lesions cogitated during puberty. Eradication by shaving is typically inadequate as it may not eliminate the entire lesion [9,10].

Cogent attributes for a successful surgical extermination include magnitude and location of lesion.

General anaesthesia is suitable for a majority of subjects, especially children.

Elimination of miniature lesions is technically simpler. Juvenile patients are not responsive to local anaesthesia or may not competently endure general anaesthesia.

Therapeutic options include surgical excision of the lesion prior to puberty with manageable reactions to local or general anaesthesia or a meticulous clinical observation of the plaque for malignant progression. Therapeutic decisions implicating nevus sebaceous incorporate a comprehensive surgical elimination of the lesion with the inclusion of an uninvolved surgical perimeter.

Employment of carbon dioxide (CO2) lasers for disposing of nevus sebaceous improves cosmetic outcome although laser mechanics partially extend up to papillary dermis. Thus, aforesaid technique of therapeutic alleviation is not recommended on account of possible malignant degeneration of remnant inferior dermal cellular composites [10,11].

Prognostic implications

Outcome of the congenital disorder is dependent upon elucidation of benign or malignant categories of nevus sebaceous during discernment of the lesion. Trichoblastoma can be misdiagnosed as a basal cell carcinoma.

Malignant transformation of benign lesions is cogitated in an estimated 10% or lesser instances. Malignant conversion is infrequently delineated in children below < 5 years of age.

Progression of a lesion to sebaceous cyst is everlasting and the cysts do not retrogress with an elapsed period of time. Basal cell carcinoma is a frequent malignant neoplasm demonstrated in nevus sebaceous whereas trichoblastoma is a common benign neoplasm [11,12].

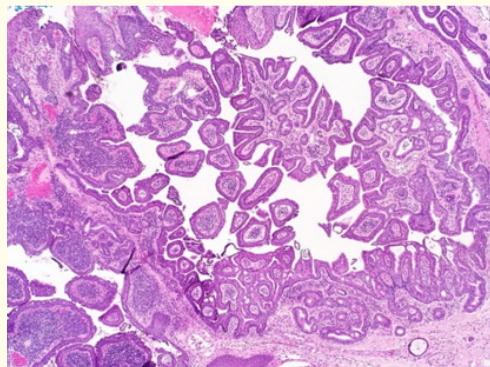


Figure 1: Papillomatosis, acanthosis and prominent sebaceous glands in nevus sebaceous [13].

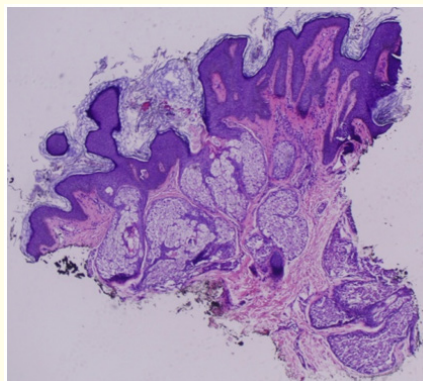


Figure 2: Epidermal hyperplasia, sebaceous preponderance, papillomatosis and apocrine gland dilatation in nevus sebaceous [14].

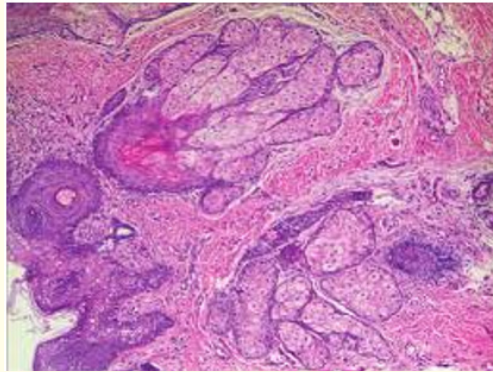


Figure 3: Sebaceous glandular hyperplasia and papillary epidermal aggregates in nevus sebaceous [15].

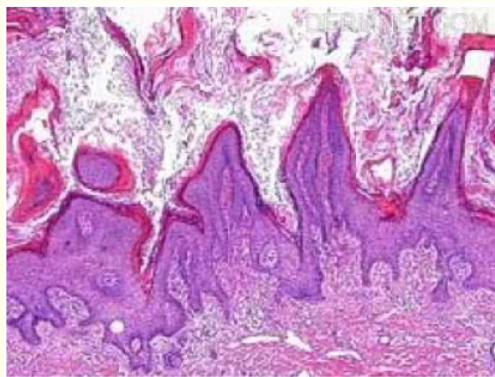


Figure 4: Papillomatosis, hyperkeratosis and immature sebaceous glands in nevus sebaceous [16].

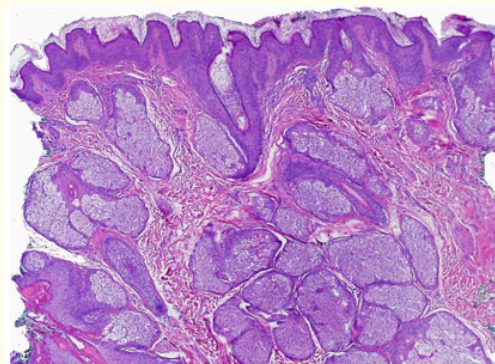


Figure 5: Mature sebaceous glands with hyperplasia and epidermal corrugation in nevus sebaceous [17].

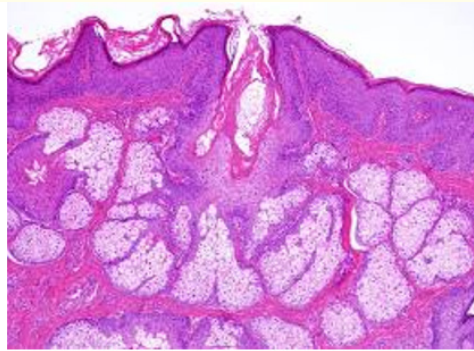


Figure 6: Mature sebaceous gland aggregates with a superficial epidermis in nevus sebaceous [18].

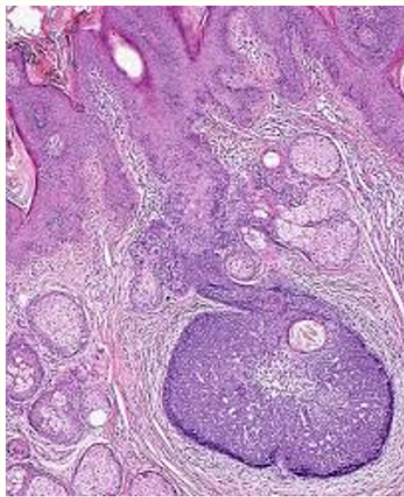


Figure 7: Immature sebaceous lobules and epidermal hypertrophy with defective hair follicles in nevus sebaceous [19].

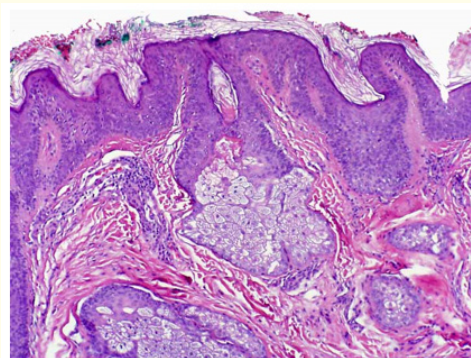


Figure 8: Primitive sebaceous lobules with epidermal hyperplasia, papillae and distended apocrine glands in nevus sebaceous [20].

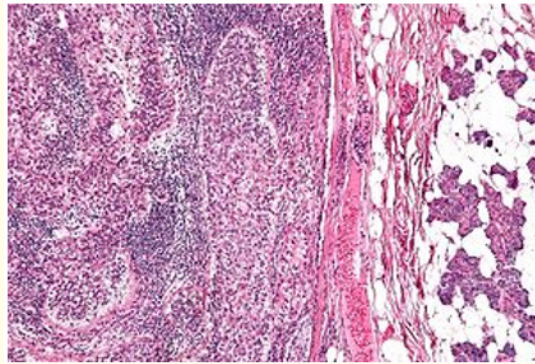


Figure 9: Distended, mature sebaceous glands in nevus sebaceous [21].

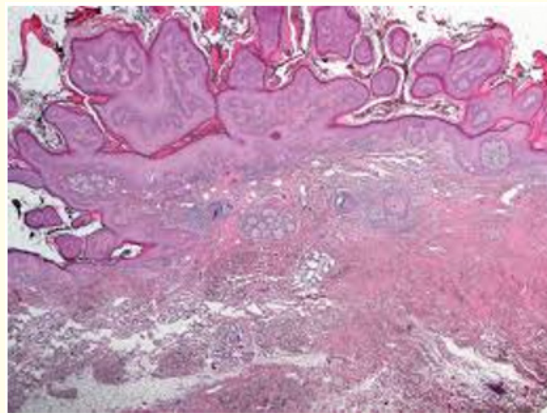


Figure 10: Immature sebaceous glands with epidermal papillae in nevus sebaceous [22].

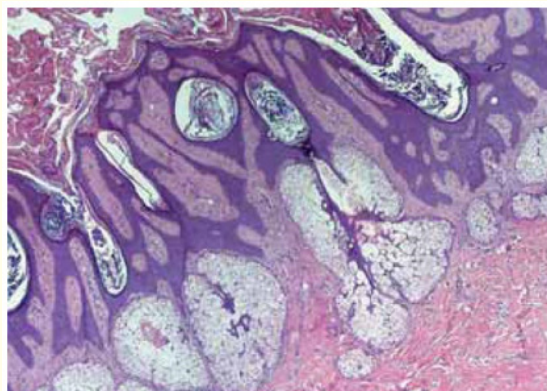


Figure 11: Mature sebaceous glands, hyperplasia and papillomatosis in nevus sebaceous [23].

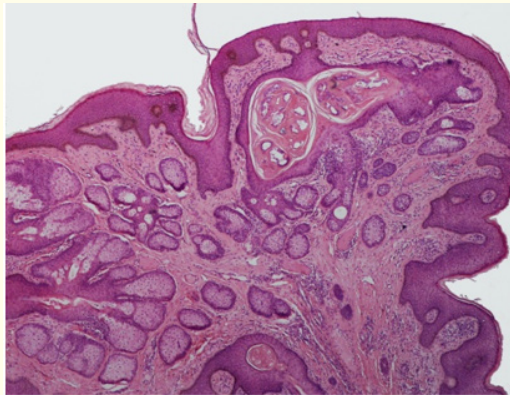


Figure 12: Mature, multiple sebaceous glands, epidermal hyperplasia, apocrine distension and aberrant hair follicles in nevus sebaceous [24].

Conclusion

Nevus sebaceous is an exceptional congenital aberration inducing a cosmetic deformity, alopecia or infrequently a malignant conversion. Lesions are cogitated at birth, evolve gradually with a rapid enlargement during puberty on account of hormonal efflux.

Basal cell carcinoma is a frequent malignant accompaniment and trichoblastoma delineates the oft encountered benign tumefaction. Therapeutic options are controversial and include early surgical eradication during childhood or adopting a policy of watchful observation.

However, unanimity for a superior therapeutic alternative is lacking. Appropriate management of nevus sebaceous is optimally decided by the subject or family or treating surgeon contingent to procedural safety and endurance of preferred anaesthesia, the desired oncologic expectations and augmentation of surgical excision in the event of excessive growth or malignant transformation.

Bibliography

1. Baigrie D and Cook C. "Nevus Sebaceous". Stat Pearls Publishing (2019).
2. Nassiri A., et al. "A yellow and a benign tumour in a newborn". *International Journal of Pediatric Health Care and Advancements* 5.2 (2018): 79-80.
3. Segars K., et al. "Nevus Sebaceous of Jadasshon". *EPlasty* 15 (2015): ic38.
4. Garcias-Ladaria J., et al. "Epidermal nevi and related syndromes- part 2. Nevi derived from adnexal structures". *Actas Dermo-Sifiliográficas* 109.8 (2018): 687-689.
5. Lobato- Berezo A., et al. "Tumour collision over nevus sebaceous: clues for dermoscopic diagnosis". *Actas Dermo-Sifiliográficas* 109.7 (2018): 647-648.
6. Wali GN., et al. "Management of nevus sebaceous; a national survey of UK dermatologists and plastic surgeons". *Clinical and Experimental Dermatology* 43.5 (2018): 589-591.
7. El Ezzi O., et al. "Syndromic sebaceous nevus: current findings". *International Journal of Dermatology* 57.5 (2018): 599-604.

8. Gu AK, *et al.* "Nevus sebaceous at an unusual location: a rare presentation". *Chinese Medical Journal* 130.23 (2017): 2897-2898.
9. Liu Y, *et al.* "Nevus sebaceous of Jadasshon with eight secondary tumours of follicular, sebaceous and sweat gland differentiation". *American Journal of Dermatopathology* 38.11 (2016): 861-866.
10. Patel P, *et al.* "Sebaceous and Becker' Nevus-Overview of their presentation, pathogenesis, associations and treatment". *American Journal of Clinical Dermatology* 16.3 (2015): 197-204.
11. Kelati A, *et al.* "Dermoscopic analysis of nevus sebaceous of Jadasshon- a study of 13 cases". *Skin Appendage Disorders* 3.2 (2017): 83-91.
12. Idriss MH and Elston DM I. "Secondary neoplasm associated with Nevus Sebaceous of Jadasshon: a study of 707 cases". *Journal of the American Academy of Dermatology* 70.2 (2014): 332-337.
13. Image 1 Courtesy: Webpathology.com.
14. Image 2 Courtesy: eScholarship.com.
15. Image 3 Courtesy: Research gate.
16. Image 4 Courtesy: You tube.
17. Image 5 Courtesy: Pathology apps.
18. Image 6 Courtesy: Twitter.
19. Image 7 Courtesy: Pathology outlines.
20. Image 8 Courtesy: Virtual grand rounds in pathology.
21. Image 9 Courtesy: Wikipedia.
22. Image 10 Courtesy: PixHD.com.
23. Image 11 Courtesy: Sceilobro.com.
24. Image 12 Courtesy: Wikimedia commons.

Volume 2 Issue 3 May 2019

©All rights reserved by Anubha Bajaj.