

Morphological Variations of Pronator Quadratus and Patterns of its Nerve Supply in Egyptian Cadavers in General

Ehab Mostafa Elzawawy* and Ayman Ahmed Khanfour

Assistant Professor in the Human Anatomy and Embryology Department, Faculty of Medicine, University of Alexandria, Egypt

***Corresponding Author:** Ehab Mostafa Elzawawy, Assistant Professor in the Human Anatomy and Embryology Department, Faculty of Medicine, University of Alexandria, Egypt.

Received: October 15, 2018; **Published:** March 04, 2019

Abstract

Introduction: Pronator quadratus (pq) muscle is very important for forearm pronation and stabilization of distal radioulnar joint. It has many morphological variations which can affect its function.

Material and Methods: This study was carried out on 100 cadaveric forearms to define the variations of pq as regards its shape, number of heads and its nerve and blood supply to create a safety margin to spare pq and its nerve and blood supply during surgery for distal radius fractures.

Results: We found that pq had one superficial head and 3 deep heads in 20% of cases and one superficial head and one deep head in 15% of cases. There were 2 superficial and 2 deep heads in 15% of cases and 3 superficial and 3 deep heads in 5% of cases. There were 2 types of anterior interosseous innervation to pq; either the nerve passed between the superficial and deep heads in 20% of cases or passed deep to all heads in 80% of cases. The branches to the superficial head entered through its deep surface in 95% of cases or through its upper border in 5% of cases. The branches to the deep head entered through the deep surface in 80% of cases or through the superficial surface in 20% of cases. The nerve mainly passed on the lateral side near the radius except near the lower border of pq where it passed medially towards the ulna.

Conclusions: These anatomical findings are crucial when planning to place plates to fix distal fractures of forearm bones. Minimally invasive procedures must be implemented to elevate only the distal lateral attachment of pq to a distance not exceeding 3.10 cm from the wrist line (wl) to avoid injury of ai or its branches to pq.

Keywords: *Pronator Quadratus; Morphological Variations; Anterior Interosseous Nerve; Radius Fractures; Safty Margin*

Introduction

The pq is a quadrilateral muscle with attachments to the anterior surface of the distal ulna and radius. It has two distinct heads; the superficial head and the deep head [1]. The superficial head acts as a pronator of forearm, while the deep head stabilizes the distal radioulnar joint [2]. However, the morphology of pq is very variable. The superficial head may be composed of single, double or triple muscle fascicles, whereas the deep head may be composed of single, double or multiple muscle fascicles. The most distal fascicle of the deep head may extend to the head of ulna [3].

The pq is innervated by anterior interosseous nerve (ai) in a steady pattern. The nerve runs from the lateral to the medial side near the distal part of the muscle. Therefore, it is recommended that surgeries for distal radial fractures should be conducted on the lateral side [3].

The distance between the branches of ai to pq and the wl is very crucial for planning the appropriate surgical approach in the repair of distal forearm fractures. The most proximal branch was located 5.4 cm above wl; and the most distal branch was located 2.5 cm above the same line, therefore, the mean point of the branches to pq was 3.6 cm above wl [4].

Open reduction and plate fixation for distal radius requires wide exposure of the fracture site which may affect blood supply of the bony fragments. Minimally invasive plate osteosynthesis (MIPO) was developed to avoid wide exposures of the fracture site and minimize damage to pq and preserve vascularity of the fractured fragments [5,6].

Knowledge of the morphological variations and innervation patterns to each head of pq is critical for preserving the function of the muscle during surgery for distal radial fracture [7].

Aim of the Study

The aim of this work was to study the anatomical variations of pq and its patterns of innervation to create a safety margin to spare pq and its nerve and blood supply during surgery for distal radial fractures.

Materials and Methods

A total of 100 forearms from 50 Egyptian adult cadavers (33 males and 17 females) were used in this study. All cadavers were obtained from the Department of Anatomy, Faculty of Medicine, University of Alexandria. Twenty forearms were injected with lead oxide, latex and water to identify blood supply of pq. All cadavers were fixed in 8% formalin and preserved in 30% ethanol. The structure of pq was observed. The number of the superficial heads of pq, their shape, length, width, origin and insertion were studied. The attachment of the superficial head (s) was dissected from the anterior surface of the ulna and reflected laterally. The deep head (d) was observed in the same manner as the superficial head. The innervation patterns of pq were investigated. The ai was dissected and its distribution to the superficial and deep heads of pq was investigated. The number of branches supplying pq and how they entered it and the distance of the most proximal and most distal branches from the wl were studied. The wl was considered as the line across the distal border of radius at the margin of lunate and scaphoid fossa. Forearm length was measured from the lateral epicondyle of the humerus to the base of styloid process of the radius. The relation between the ai nerve and vessels and their branches to pq were studied in the injected specimens. All measurements were taken using Vernier caliper. Statistical analysis was done using Statistical Package for Social Sciences (SPSS/version 20) software [8].

Results

The pq had 1, 2 or 3 superficial heads (Figures 1-4) and 1, 2, 3 or 4 deep heads (Figures 5-11 and Table 1). There was one superficial head in 48 cases. It was quadrilateral in all cases. It was accompanied by one deep head in 15 cases (Figure 7) or by 3 deep heads in 20 cases (Figure 9). There were 2 superficial and 2 deep heads in 15cases (Figure 5). There were 3 superficial and 3 deep heads in 5cases (Figure 10).

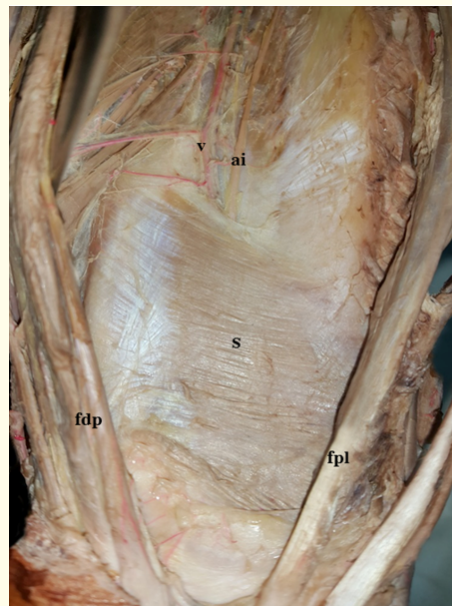


Figure 1: Left sided single superficial head of pq (s). Anterior interosseous nerve (ai) and vessels (v) pass deep to it. Flexor digitorum profundus (fdp) is seen medially, while flexor pollicis longus (fpl) is seen laterally.

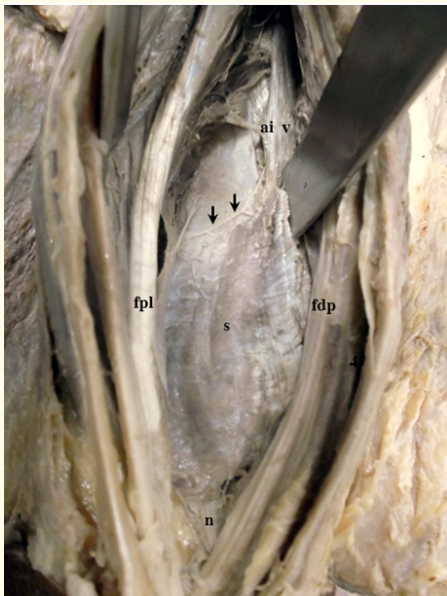


Figure 2: Right sided single superficial head of pq (s). Anterior interosseous nerve (ai) and vessels (v) pass deep to it. The nerve gives a branch (arrows) that runs on the upper border of the muscle and supplies it. The distal part of the nerve (n) emerges from the distal border of the muscle. Flexor digitorum profundus (fdp) is seen medially, while flexor pollicis longus (fpl) is seen laterally.

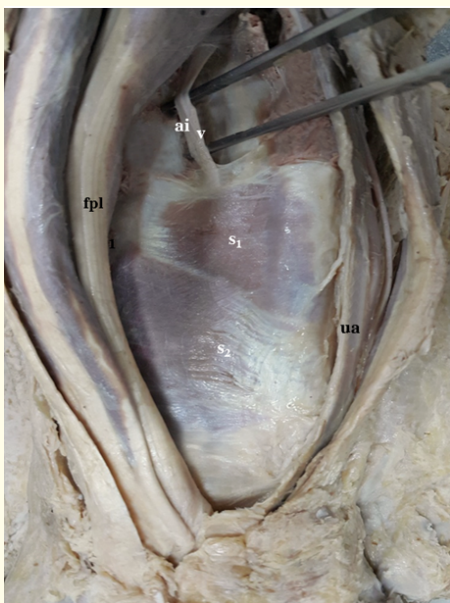


Figure 3: Right sided pq. It has 2 superficial heads (s₁, s₂). The anterior interosseous nerve (ai) and vessels (v) pass deep to it. The ulnar artery (ua) is seen on the medial side while flexor pollicis longus (fpl) is seen laterally.

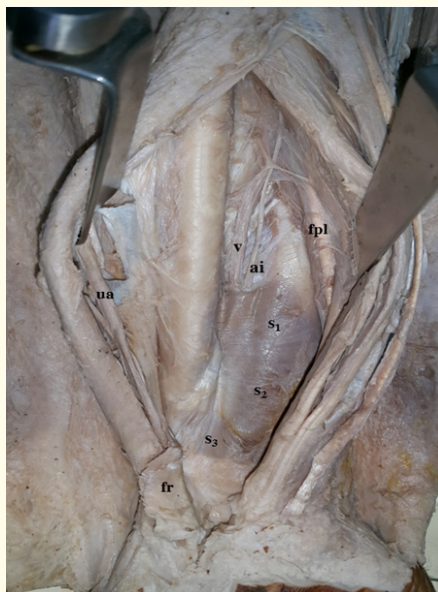


Figure 4: Left sided pq. It has 3 superficial heads (s_1, s_2, s_3). The anterior interosseous nerve (ai) and vessels (v) pass deep to it. Ulnar artery (ua) is seen medially and flexor pollicis longus (fpl) is seen laterally. Flexor retinaculum (fr) is cut and reflected medially.

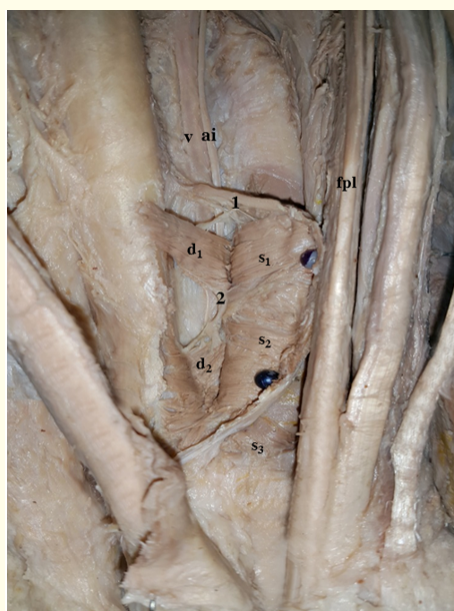


Figure 5: Left sided pq (previous specimen). It has 3 superficial heads (s_1, s_2, s_3). s_1 and s_2 were reflected to show 2 deep heads (d_1, d_2). The anterior interosseous nerve (ai) and vessels (v) pass deep to both superficial and deep heads. The nerve gives branch (1) that divides to supply s_1 and d_1 and branch (2) that supplies s_2 and d_2 .

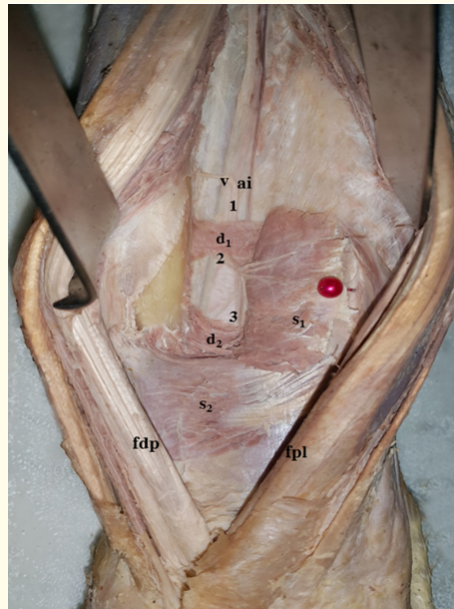


Figure 6: Left sided pq. It has 2 superficial heads (s_1, s_2) and 2 deep heads (d_1, d_2). The anterior interosseous nerve (ai) passes deep to all heads. It gives branch (1) to d_1 , branch (2) that divides into smaller branches to supply s_1 and branch (3) to s_2 and d_2 . Anterior interosseous vessels (v) are noted. Flexor digitorum profundus (fdp) is seen medially, while flexor pollicis longus (fpl) is seen laterally.

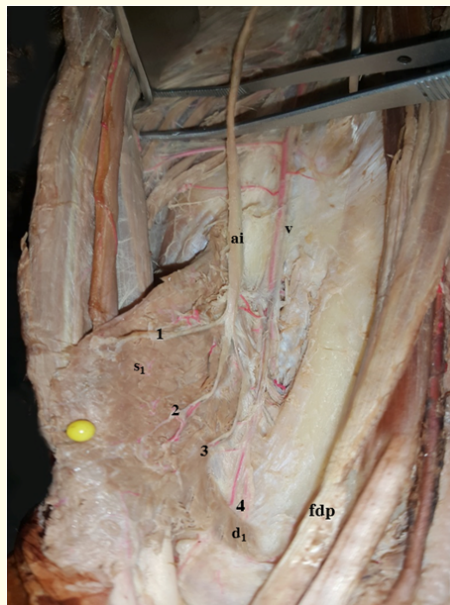


Figure 7: Right sided pq. It has one superficial head (s_1) and one deep head (d_1). The anterior interosseous nerve (ai) and vessels (v) pass deep to both heads. The nerve gives branches 1, 2, 3 to s_1 and branch 4 to d_1 . The nerve branches are accompanied by similar branches from the vessels. Tendon of flexor digitorum profundus (fdp) is seen on the medial side.

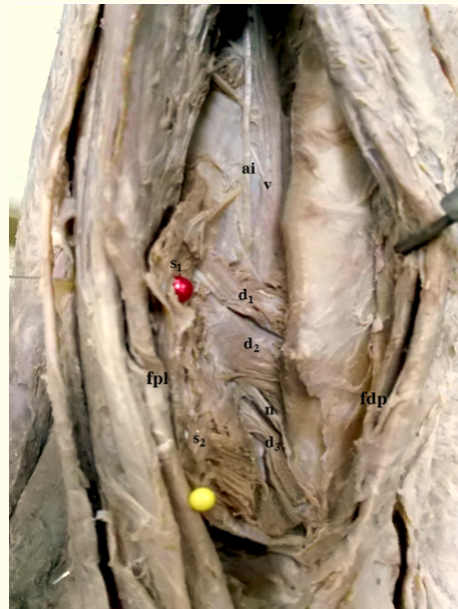

Figure 8: Right sided pq. It has 2 superficial heads (s_1, s_2) and 3 deep heads (d_1, d_2, d_3). The anterior interosseous nerve (ai) and vessels (v) pass deep to all heads. The distal part of the nerve (n) reappears lower down between d_2, d_3 where it changes its course from lateral to medial. Flexor digitorum profundus (fdp) is seen medially, while flexor pollicis longus (fpl) is seen laterally.

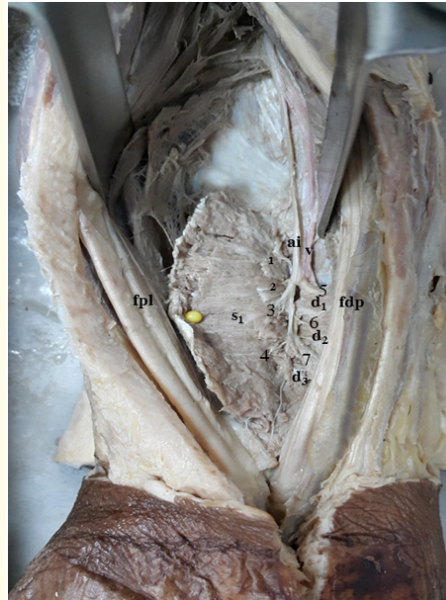


Figure 9: Right sided pq. It has a single superficial head (s_1) and 3 deep heads (d_1, d_2, d_3). The anterior interosseous nerve (ai) passes between the superficial and deep heads. It gives 4 branches (1- 4) to s_1 and 3 branches (5, 6, 7) to d_1, d_2, d_3 respectively. The anterior interosseous vessels (v) are noted. Flexor digitorum profundus (fdp) is seen medially, while flexor pollicis longus (fpl) is seen laterally.

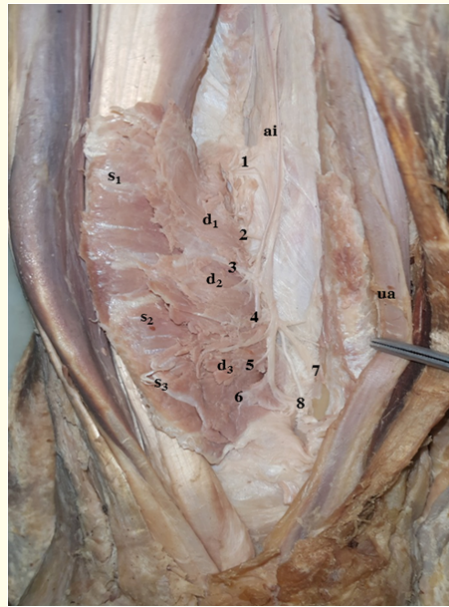


Figure 10: Right sided pq. It has 3 superficial heads (s_1, s_2, s_3) and 3 deep heads (d_1, d_2, d_3). The anterior interosseous nerve (ai) passes deep to all heads, and gives branches (1- 8). Branches (1, 2) supply s_1, d_1 , branches (3, 4) supply s_2, d_2 , branches (5, 6) supply s_3, d_3 and branches (7, 8) are the continuation of the nerve and supply the joints. The ulnar artery (ua) is seen on the medial side.

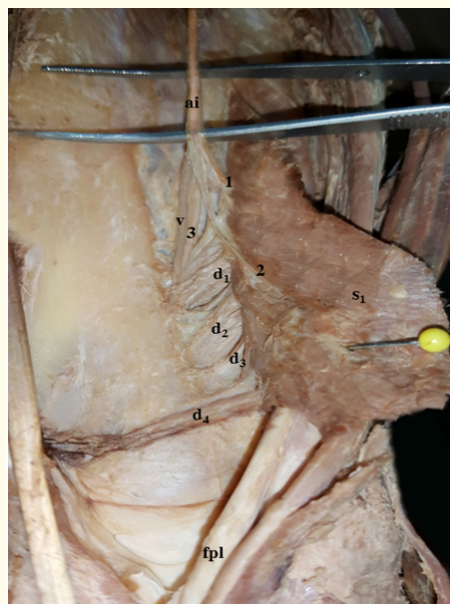


Figure 10: Left sided pq. It has a single superficial head (s_1) and 4 deep heads (d_1, d_2, d_3, d_4). The anterior interosseous nerve (ai) gives branch 1 to s_1 and branch 2 which divides to supply s_1 and d_1 and continues downwards as (3) which supplies d_2, d_3, d_4 . The anterior interosseous vessels (v) are noted. Tendon of flexor pollicis longus (fpl) is seen laterally.

No. of superficial heads of pq.	Number of deep heads of pq.				Total
	1	2	3	4	
1	15%	10%	20%	3%	48%
2	10%	15%	5%	-	30%
3	10%	7%	5%	-	22%
Total	35%	32%	30%	3%	100%

Table 1: Number of superficial and deep heads of pq.

In case of 2 superficial heads, the 2 heads were quadrilateral in shape; the proximal head was inserted into radius, while the distal head was inserted into ulna (Figure 3). The distal superficial head was thicker than the proximal one (Figure 6).

In case of 3 superficial heads, the distal head was triangular in shape, and attached medially to the head of ulna in all cases (Figure 4). In case of 4 deep heads, the distal head was a slender transverse fascicle attached to the head of ulna in all cases (Figure 11).

In case of 2 deep heads, the proximal head ran obliquely from proximal ulnar origin to the distal radial insertion, while the distal deep head ran obliquely from proximal radial origin to distal ulnar insertion (Figure 5).

The length of pq ranged from 5 - 8.8 cm with a mean of 6.54 ± 0.79 cm, while its width ranged from 3 - 4.97 cm with a mean of 3.99 ± 0.63 cm. The mean distance (dw) between its distal border and wl was 1.56 ± 0.27 cm.

The mean length of ai was 17.84 ± 1.45 cm, while the mean forearm length was 26.19 ± 1.85 cm. The proximal branch of ai arose at a mean distance (dp) of 5.42 ± 0.48 cm from wl, while the distal branch of ai arose at a mean distance (dd) of 2.61 ± 0.38 cm from wl (Table 2).

	Forearm length	Length of ai	pq Length	pq Width	dw	dp	dd
N	100	100	100	100	100	100	100
Mean	26.19	17.84	6.54	3.99	1.56	5.42	2.61
Median	26.00	17.50	6.50	3.75	1.50	5.10	2.48
Std. Deviation	1.85	1.45	0.79	0.63	0.27	0.48	0.38
Minimum	23.10	14.20	5.00	3.00	1.00	4.60	1.80
Maximum	29.60	21.10	8.80	4.97	2.10	6.13	3.10

Table 2: Measurements of pq and ai.

dw: Distance of distal border of pq to wl; *dp:* Distance of proximal branch of ai to wl; *dd:* Distance of distal branch of ai to wl.

The ai nerve gave from 3 - 8 branches to supply pq with an average of 5.37 ± 1.35 (Figures 7, 9, 10). The superficial head received from 1 - 5 branches with a mean of 2.95 ± 0.93 , while the deep head received from 1 - 4 branches with a mean of 1.85 ± 0.70 . Some of these branches divided into several smaller branches before entering the muscle (Figure 6). Joint branches that divided to supply the superficial and deep heads simultaneously were found in 40% of cases (Figures 5, 6, 10 and Table 3).

	To superficial head	To deep head	Joint branches	Total
N	100	100	100	100
Mean	2.95	1.85	0.47	5.37
Median	3.00	2.00	0.50	5.50
Std. Deviation	0.93	0.70	0.46	1.35
Minimum	1.00	1.00	0.00	3.00
Maximum	5.00	4.00	1.00	8.00

Table 3: Number of ai branches to pq.

The ai nerve and vessels passed deep to the upper border of pq in all cases (Figures 1-11). They passed between the superficial and deep heads of the muscle in 20% of cases (Figure 9). In 80% of cases, the nerve and vessels passed deep to all heads (Figures 5-8).

In 5 cases (5%), the nerve gave a branch that ran on the upper border of the superficial head and supplied it (Figure 2). Otherwise, the superficial heads were supplied through their deep surface (95%) (Figures 5-11). The deep heads received nerve supply through their superficial surface in 20% of cases (Figure 5 and 9) or through their deep surface in 80% of cases (Figures 6-8 and 10).

There were two branching patterns of the ai nerve:

1. In 20% of cases: the nerve passed between the superficial and deep heads and immediately divided to supply superficial heads from their deep surface and the deep heads from their superficial surface (Figure 9).
2. In 80% of cases: the nerve passed deep to all heads and gradually branched to supply the deep heads from their deep surface and the superficial heads were supplied by branches that passed through the deep heads (Figure 10).

As the ai passed through or deep to pq, it ran on the lateral side towards radius throughout most of the muscle. It passed medially at the distal end of the muscle after giving off its most distal branch to pq (Figure 8). That is why; we detached pq from its medial attachment to ulna to safe guard the nerve during dissection.

The ai vessels were on the medial side of the nerve in all cases (Figures 1-11). The branches of the nerve to the superficial or deep heads of pq were accompanied by branches from the vessels in all injected specimens (Figure 7 and 9).

Discussion

There are so many morphological variations of pq. Surekha, *et al.* [9] classified 9 different types of pq according to the number and shape of its superficial and deep heads. These variations can hinder orthopedic procedures in the distal forearm.

Gordon, *et al.* [10] confirmed that pq is a major contributor to forearm pronation and its deep head acts primarily as a dynamic distal radioulnar joint stabilizer. A fact that must be kept in mind when planning surgical procedures and rehabilitation strategies.

We detected variable number and shapes of pq heads and so did many other authors [3,11-13]. Das, *et al.* [11] reported a double headed pq with different fiber directions of each head. They stated that such variation can alter the biomechanics of the radioulnar joints and is extremely beneficial for orthopedic and transplant surgeons.

Sakamoto, *et al.* [3] reported a single superficial head of pq in 62.5%, double heads in 27.5% and triple heads in 10.0% of cases compared to 48%, 30% and 22% respectively in our cases. They found a single deep head in 25%, double heads in 57.5%, triple heads in 15.0% and quadruple heads in 2.5% compared to 35%, 32%, 30% and 3% respectively in our cases. This shows that the same variations can occur in different races but in different proportions.

In the present work, the most distal (3rd) superficial head of pq is triangular, its apex is proximal while its base is distal and attached to the head of ulna. This muscle moves the head of ulna upwards and prevents it from impacting against the articular disc. The most distal (3rd or 4th) deep head runs transversely across the distal radioulnar joint and stabilizes it as previously observed by Stuart [14].

Imatani, *et al.* [15] believe that it is crucial to preserve the rich vascularity and nerve supply of the distal radius and ulna and advice fixation of fractures in this region using MIPO techniques. Therefore, thorough knowledge of the anatomy of pq and its blood and nerve supply is crucial for successful MIPO.

Choung, *et al.* [16] described motor entry points of the branches of ai into pq in the distal 13% of forearm length. This is important for insertion of electromyography needle and injection of neurolytic agents for treating pronator spasticity in stroke patients.

Grafe, *et al.* [17] reported that the average number of ai branches to pq was 4.9. Lin, *et al.* [18] reported that there was an average of 3 motor branches from ai to pq. We found that the mean number of ai branches supplying pq was 5.37 ± 1.35 . The mean number of branches to the superficial head was 2.95 ± 0.93 while the mean number of branches to the deep head was 1.85 ± 0.70 . Joint branches supplying both heads were found in 40% of cases.

Sakamoto, *et al.* [3] stated that ai gave 3 - 4 branches to pq. These branches supplied the muscle from its deep surface. Some branches penetrated through the deep head, ran laterally and innervated the superficial head. Other branches divided to supply the superficial and deep heads (joint branches). We observed similar innervation patterns. In addition we found that the deep heads are sometimes supplied from their superficial surface and the superficial heads can receive nerve supply from branches running on the upper border of the muscle.

Svizenska, *et al.* [19] observed three types of ai branching patterns: gradual branching, terminal branching, and terminal branches that continue to the wrist joint. We observed 2 branching patterns; the first is immediate branching as ai passed between the superficial and deep heads of pq. The second pattern is gradual branching as the nerve passed deep to all heads. The nerve continued to supply the joints in both patterns.

It is imperative to elevate the distal border of pq to place volar plates to fix fractures of lower end radius or ulna [20]. Of course, it is much easier to place volar plates in the first pattern as the nerve passes inside the muscle and is protected by its fibers. Unfortunately, the second pattern is more common (80%) and the nerve passes deep to the muscle and is prone to injury during volar plates fixation for distal radial fractures.

Rey, *et al.* [21] used pq sparing technique during MIPO for fracture lower end radius. They described elevation of the most distal lateral attachment of pq to preserve the muscle and its nerve supply. This is because a more proximal approach can injure the nerve or its branches. It is safer to elevate the lateral attachment because ai runs medially towards ulna at the lower end of the muscle.

All ai nerve branches were accompanied by similar branches from anterior interosseous vessels. If nerve branches are severed during volar plate fixation, the vessels will be severed as well. Therefore, judicious application of volar plates is essential to preserve blood supply of fractured bones.

Heidari, *et al.* [22] reported that the mean distance from the distal edge of pq to the wl was 1.31 cm laterally and 1.07 mm medially. They increased the distance to 2.62 cm laterally and 2.38 cm medially after considering the location of the distal ai branch to pq. They confirmed that this distance allows for placement of a volar plate and insertion of locking screws without damage to pq or its nerve supply.

In our study, according to the entry point of the distal branch of ai into pq, the distal margin of pq can be released to create a safety margin from 1.8 - 3.1 cm with a mean of 2.61 ± 0.38 cm (Table 2). This is where the ai nerve changes its course and runs medially. So, it is safe to intervene at the lateral side distal to this point. According to our regression analysis study, this distance can be calculated by dividing forearm length by 10.9 (Table 4).

Model	Unstandardized Coefficients		t	Sig.
	B	Std. Error		
(Constant)	2.094	0.209	10.01	0.0001
Forearm length	0.176	0.008	21.97	0.0001
Equation: $Y (dd) = (0.176 X \text{ forearm length}) - 2.094$ For each 10.9 cm of forearm length = 1 cm of dd.				

Table 4: Regression analysis of dd in relation to forearm length.

Conclusion

It is essential to create a safety margin while placing volar plates and screws to fix distal radius fractures. This distance is important to spare pq and save its nerve and blood supply. The distance can be calculated by dividing forearm length by 10.9.

Declaration

The authors declare that there is no conflict of interest regarding this article.

Bibliography

1. Johnson D and Ellis H. "Pectoral girdle and upper limb". In: Standring S (ed) Gray's Anatomy, 39th edition. Edinburgh, London, Elsevier Churchill Livingstone (2005): 848.
2. Mcconkey MO., et al. "Quantification of pronator quadratus contribution to isometric pronation torque of the forearm". *Journal of Hand Surgery-American Volume* 34.9 (2009): 1612-1617.
3. Sakamoto K., et al. "An anatomic study of the structure and innervation of the pronator quadratus muscle". *Anatomical Science International* 90.2 (2015): 82-88.
4. Alves N., et al. "Innervation of the pronator quadratus muscle". *International Journal of Morphology* 22.4 (2004): 253-256.
5. Sen MK and Harvey EJ. "Minimally invasive plate osteosynthesis of distal radius fractures using a pronator sparing approach". *Techniques in Hand and Upper Extremity Surgery* 12.1 (2008): 2-6.
6. Takada N and Otsuka T. "Anatomical features of the pronator quadratus muscle related to minimally invasive plate osteosynthesis of distal radial fractures with a volar locking plate: a cadaver study". *European Orthopaedics and Traumatology* 2.5-6 (2011): 133-136.
7. Lo HY and Cheng HY. "Clinical study of the pronator quadratus muscle: anatomical features and feasibility of pronator-sparing surgery". *BMC Musculoskeletal Disorders* 15 (2014): 136.
8. Kirkpatrick LA and Feeney BC. "A Simple Guide to IBM SPSS Statistics Version 20". Cengage Learning, Belmont, California, USA (2013).
9. Surekha JD., et al. "Morphology of pronator quadratus muscle: a cadaveric study". *International Journal of Medical Research and Health Sciences* 3.4 (2014): 876-879.
10. Gordon KD., et al. "Electromyographic activity and strength during maximum isometric pronation and supination efforts in healthy adults". *Journal of Orthopaedic Research* 22.1 (2004): 208-213.
11. Das S., et al. "Anomalous pronator quadratus muscle: a case report". *European Journal of Anatomy* 12.2 (2008): 123-125.
12. Demir S., et al. "Bilateral pronator quadratus muscle variation". *Annals of Medical Sciences* 10 (2001): 180-181.
13. Annis RS. "Pronator quadratus - a forgotten muscle: a case report". *Journal of the Canadian Chiropractic Association* 47.1 (2003): 17-20.

14. Stuart PR. "Pronator quadratus revisited". *Journal of Hand Surgery (British Volume)* 21.6 (1996): 714-722.
15. Imatani J, et al. "Minimally invasive plate osteosynthesis for comminuted fractures of the metaphysis of the radius". *Journal of Hand Surgery (British Volume)* 30.2 (2005): 220-225.
16. Choung PW, et al. "Anatomic Characteristics of Pronator Quadratus Muscle: A Cadaver Study". *Annals of Rehabilitation Medicine* 40.3 (2016): 496-501.
17. Grafe MW, et al. "Wrist denervation and the anterior interosseous nerve: anatomic considerations". *Journal of Hand Surgery-American Volume* 30.6 (2005): 1221-1225.
18. Lin DL, et al. "Anatomy of the anterior interosseous innervation of the pronator quadratus: evaluation of structures at risk in the single dorsal incision wrist denervation technique". *Journal of Hand Surgery-American Volume* 31.6 (2006): 904-907.
19. Svizenska I, et al. "An anatomical study of the anterior interosseous nerve and its innervation of the pronator quadratus muscle". *Journal of Hand Surgery* 30.6 (2005): 635-637.
20. Tarallo L, et al. "Volar plate fixation for the treatment of distal radius fractures: analysis of adverse events". *Journal of Orthopaedic Trauma* 27.12 (2013): 740-745.
21. Rey PB, et al. "Technical note: How to spare the pronator quadratus during MIPO of distal radius fractures by using a mini-volar plate". *Chirurgie de la Main* 33.2 (2014): 95-99.
22. Heidari N, et al. "Is sparing the pronator quadratus muscle possible in volar plating of the distal radius?" *Journal of Hand Surgery* 37.5 (2012): 402-406.

Volume 2 Issue 1 March 2018

©All rights reserved by Ehab Mostafa Elzawawy and Ayman Ahmed Khanfour.