

## Delayed Effects of Intentional Amlodipine Overdose in a Young Pregnant Woman

Bhavna P Singh<sup>1\*</sup>, Anand B Mamdapur<sup>2</sup> and Madhusudan R<sup>3</sup>

<sup>1</sup>Attending Consultant in Critical Care, Sakra World Hospital, Bangalore, India

<sup>2</sup>Senior Consultant and Head of Department of Critical Care, Sakra World Hospital, Bangalore, India

<sup>3</sup>Senior Consultant in Critical Care, Sakra World Hospital, Bangalore, India

**\*Corresponding Author:** Bhavna P Singh, Attending Consultant in Critical Care, Sakra World Hospital, Bangalore, India.

**Received:** January 25, 2020; **Published:** February 24, 2020

### Abstract

Amlodipine classified as a di-hyropyridine calcium channel blocker has an elimination half-life of 40 - 60 hours, a delayed onset of action and a large volume of distribution. We report a young pregnant lady who intentionally consumed 375 mg of Amlodipine and presented to us 20 hours later with severe hemodynamic instability which responded initially to a guideline directed treatment consisting of Calcium, Hyper insulin euglycemic therapy, glucagon, intralipid and vasopressor support. Other supportive therapies included mechanical ventilation and continuous renal replacement therapy in a CVVHD mode. However, the intention of reporting this case is to highlight the delayed effects of amlodipine which include a syndrome similar to systemic capillary leak syndrome with extensive peripheral edema, bilateral massive pleural effusions and a life-threatening pericardial effusion which needed immediate intervention. Due to paucity of literature in this area we hope that our case report improves the management of these patients including anticipating these problems, early referral to a tertiary care center and promotes research in this area.

**Keywords:** Amlodipine; Calcium Channel Blocker

### Introduction

Amlodipine classified as a di-hyropyridine calcium channel blocker has an elimination half-life of 40 - 60 hours and a delayed onset of action and a large volume of distribution [1]. Its overdose is uncommon and about 9500 cases have been reported worldwide [2]. It is more uncommon in developing countries like India where the access to pesticides are easy making organophosphates the most commonly consumed substance. Here we would like to report a rare case of a young pregnant lady consumed 375 mg of Amlodipine with suicidal intent and came to our ICU 20 hours later. We would like to highlight both the acute and delayed effects of Amlodipine overdose which have rarely been reported in current literature.

### Case Report

A 27-year-old female patient an engineer by profession with 16 weeks gestation hailing from central India presented to our tertiary care intensive care unit after being referred from secondary care center about 20 hours after consuming 75 Tablets of Amlodipine 5 mg with a suicidal intent. She had been earlier resuscitated with gastric lavage, intravenous fluids and was initiated on Inj Noradrenaline 0.5 µg/kg/min to support her blood pressure.

On arrival she was Hypotensive requiring escalating doses of vasopressors. A 7FR triple lumen access, a 20 G right radial arterial line and an 18 Fr Foley catheter were inserted. She was still conscious although she had a pattern of Kussmaul's acidotic breathing for which she was intubated with a 7.5 mm endotracheal tube and initiated on mechanical ventilation with a Maquet ventilator PRVC tidal volume

450 cc, RR 18/min, FiO<sub>2</sub> of 60% Peak pressures were 26 cm of H<sub>2</sub>O. A FloTrac monitor EDWARDS EV1000 series was connected for Cardiac output monitoring. It showed an increased cardiac output with a low systemic vascular resistance. Additionally, a fetal Doppler was performed hourly.

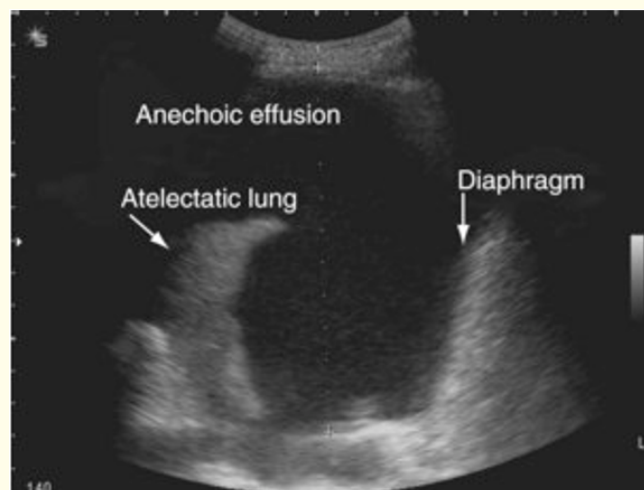
Initial Labs showed evidence of acute kidney injury, severe metabolic acidosis with elevated lactates and hyperkalemia. All other investigations were relatively normal. Serum Amlodipine levels were not sent due to delayed presentation, difficulties and delays in obtaining results early in our set up.

We initiated resuscitation as per our institutional protocol for calcium channel blocker overdose with Inj Calcium Chloride 1g/hour; hyper insulin euglycemic therapy (HIET) which is Inj Novorapid 25 units/hr with Inj Dextrose 25 - 50 g/hr depending on an hourly blood sugar check; Inj Adrenaline 0.05 - 1 µg/kg/min titrated to an invasive blood pressure monitor and Inj Glucagon 1 mg/hour. Since she failed to respond to above measures Inj Intralipid 20% at 20 ml/hr. A veno arterial extracorporeal membrane oxygenation was being planned as a last resort. Continuous renal replacement therapy (CRRT- CVVHD) was initiated due to severe acidosis, oliguria and hyperkalemia.

Over the next few hours she did show a response to the above management without ECMO and hence all the medications and CRRT were continued for the next 24 hours. The fetal Doppler showed a steady fetal heart rate without variation. She was weaned off vasopressor support gradually and supportive medications were withdrawn slowly. However unfortunately there was a fetal demise during this time and a medically induced abortion was undertaken and products expelled.

She remained hemodynamically stable, started making adequate urine with resolution of acidosis and hyperkalemia, eventually weaned off the ventilator and extubated successfully by 6<sup>th</sup> day of admission.

However, after 12 hours of clinical stability she became tachypneic (RR>40/min) and hypoxic (SpO<sub>2</sub> < 84%) requiring increased oxygen delivery to maintain a normal saturation > 94%. A bedside chest ultrasound showed bilateral extensive pleural effusions with basal lung collapse (Figure 1). Cardiac examination including 2DECHO was normal at this time. She was diagnosed of non-cardiogenic pleural effusion and bilateral pleural drains were inserted which drained 1.5 litres of serous straw coloured fluid later proved to be a transudate on each side. The fluid was drained gradually to avoid re-expansion pulmonary edema. She was reintubated with a 7.5 mm endotracheal tube due to persistent tachypnea and hypoxemia. Very interestingly the interesting thing is that the pleural drains continued to drain about 1.5 - 2 litres of serous fluid every day for the next 3 days.



**Figure 1:** Ultrasound image of extensive pleural effusion with lung collapse.

On D8 of admission she developed sudden hypotension (Blood Pressure 76/45 mm Hg) and was reinitiated on vasopressor support as above. An emergency 2D Echocardiogram showed a large pericardial effusion with features of cardiac tamponade (Figure 2). A bedside emergency pericardiocentesis was performed which drained 510 cc of serous straw coloured fluid which was a transudate. A pericardial drain was left in place for intermittent aspiration and 2D Echocardiogram scans were performed bedside every 4 - 6 hours.

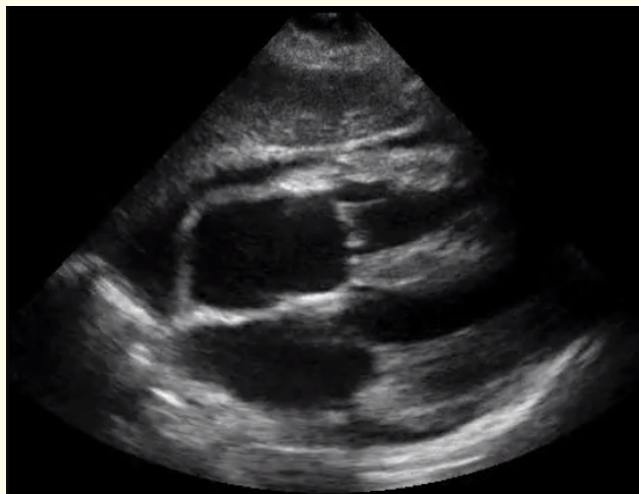

Figure 2: Apical 4 chamber view showing features of cardiac tamponade.

By D12 of admission the pericardial fluid drain was minimal the pleural drains were < 200 cc. Hence gradually one after the other the drains were removed and she was extubated. Obviously, we continued to monitor her for signs of deterioration for the next 48 hours.

She remained stable and was transferred to the floor where a psychiatric evaluation diagnosed her of depression with borderline personality traits. She was started on antidepressant medications and underwent extensive psychiatric counselling. She was finally discharged home fully stable after 17 days of hospital stay. At one month follow up she was doing well, had an excellent support system with her family and was grateful to us for our efforts.

### Discussion and Conclusion

Amlodipine Besylate is classified as a di-hydropyridine calcium channel blocker has an elimination half-life of 40 - 60 hours and a delayed onset of action [1]. It acts on L type of calcium channels in the vascular system causing vasodilatation with almost no effects on myocardial calcium channels. It also acts on calcium channels in the beta cells of pancreas causing hyperglycemia. Its overdose is uncommon and about 9500 cases have been reported worldwide [2]. Acute calcium channel blocker overdose is well documented however the therapies are still evolving. The first consensus guideline for treatment was published in 2017 [3]. However, most of the evidence was low grade with weak evidence. Gastric lavage is useful if the patient presents within one hour after consumption. Whole bowel irrigation and activated charcoal may have some benefit over the first 24 hours but not without complications like vomiting, aspiration and intestinal obstruction. The first line treatment is intravenous calcium which improves blood pressure and contractility. The second most proven therapy included hyper insulin euglycemic therapy (HIET) [4]. The mechanism postulated is that insulin improves entry of glucose and oxygen into myocardial cells. It also has calcium dependent inotropic effects and improves microcirculation. Evidence and preliminary studies do show an improved blood pressure with decreasing vasopressor requirement when used early in patients with calcium channel blocker overdose. There is evidence for high dose glucagon since it increases availability of cAMP at cellular level improving contractility. Vasopressors of choice include Nor adrenaline, Adrenaline and vasopressin. Inodilators like milrinone and dobutamine are used if there

is evidence of cardiac dysfunction which is more common among the phenylalkylamine and benzothiazepine class of calcium channel blockers like verapamil and diltiazem. Levosimendan can also be used for improving contractility. Intravenous lipid emulsions can be tried in refractory cardiogenic or vasodilatory shock since it acts as a lipid sink to reduce the toxic effects. Methylene blue can be used at 1 - 2 mg/kg in refractory vasodilatory shock since it causes vasoconstriction by acting on the NO-cGMP pathway [5].

Veno arterial ECMO and cardiac pacing are used in refractory shock and severe bradycardia unresponsive to Atropine. The role of plasma exchange therapy and charcoal hemoperfusion are unclear at this time.

The present case report was intended to highlight the delayed effects of amlodipine overdose an extensive search over PubMed and google scholar showed how scarcely this phenomenon has been reported. M Hediatty, *et al.* reported a case of Non cardiogenic pulmonary edema in 2015 [6]. They attributed this rare side effect to pulmonary pre-capillary vasodilatation causing increase in hydrostatic pressure leading to interstitial edema. V Upreti, *et al.* reported a case with similar finding of bilateral pleural effusions in amlodipine overdose [7]. They attributed it to a generalized vasodilatation causing a systemic capillary leak syndrome similar to septic shock, anaphylaxis and ovarian hyperstimulation syndrome. Overzealous fluid resuscitation was one of the factors contributing to systemic capillary leak syndrome. Another unusual presentation of amlodipine overdose is acute respiratory distress syndrome probably by a similar mechanism.

A narrative review of systemic capillary leak syndrome or Clarksons disease was done in 2010 [8]. It is characterized by transient, severe, reversible hemoconcentration and hypoalbuminemia due to leakage of fluids and macromolecules into tissues. These patients were found to have elevated cytokines, increased CD25 cells circulating in blood. The patients experienced a leak phase where they experienced generalized edema and third space losses as in our patient with pleural and pericardial effusions. This was followed by a post leak phase where there was diuresis and restoration of intravascular volume. Our patient had all these stages making it one of the rarest presentations of amlodipine overdose.

A similar clinical presentation was reported by a turkey group in 2016 with bilateral pleural effusions in a patient who had consumed 300 mg of amlodipine. Their patient responded to pleural tapping, respiratory support with continuous positive airway pressure and HIET [9].

We postulate that our patient who developed extensive bilateral pleural effusions and a life-threatening pericardial tamponade suffered from these rare complications due to Amlodipine s unique action on precapillary arterioles causing vasodilatation and increased hydrostatic pressure leading to capillary leakage and third space loss. The reversal of all these findings keeping in timeline with the elimination of amlodipine further prove that these side effects must be taken seriously and further studies are needed.

### Key Messages

- Amlodipine overdose can have a variable presentation ranging from severe vasodilatory shock to a systemic capillary leak syndrome, bilateral pleural effusions, cardiac tamponade, Acute respiratory distress syndrome.
- Guideline directed therapy has been proven to improve the hemodynamics and survival of these patients.
- Amlodipine has unique mechanisms of action which need to be further studied. A very common side effect of peripheral edema when amlodipine is prescribed for hypertension is possibly due to a similar mechanism.
- Over the counter availability and selling drugs without prescription needs strict governing laws especially in developing countries.

### Acknowledgements

The care of this critically ill patient could not have been successful without a massive team effort from all the clinicians in departments of Critical Care, Cardiology, Interventional Radiology, Cardiothoracic and vascular surgery and last but not the least the hardworking and dedicated support staff including nurses and technicians.

### Conflicts of Interest

None declared.

### Bibliography

1. Abernethy DR. "Pharmacokinetics and pharmacodynamics of amlodipine". *Cardiology* 80.1 (1992): 31-36.
2. Watson WA, et al. "2002 annual report of the American Association of Poison Control Centers Toxic Exposure Surveillance System". *American Journal of Emergency Medicine* 21 (2003): 353.
3. Maude SO, et al. "Experts Consensus Recommendations for the Management of Calcium Channel Blocker Poisoning in Adults". *Critical Care Medicine* 45.3 (2017).
4. Graudins A, et al. "Calcium channel antagonist and beta-blocker overdose: antidotes and adjunct therapies". *British Journal of Clinical Pharmacology* 81.3 (2016): 453-461.
5. Jang DH, et al. "Methylene Blue for distributive shock: A potential new use of an Old Antidote". *Journal of Medical Toxicology* 9.3 (2013): 242-249.
6. Hedaiaty M, et al. "Noncardiogenic pulmonary edema after amlodipine overdose without refractory hypotension and bradycardia". *Case Reports in Emergency Medicine* (2015): 546012.
7. Upreti V, et al. "Shock due to amlodipine overdose". *Indian Journal of Critical Care Medicine* 17.6 (2013): 375-377.
8. Druey MK and Greipp RP. "Narrative Review: Clarkson Disease-Systemic Capillary leak syndrome". *Annals of Internal Medicine* 153.2 (2010): 90-98.
9. Karaca O, et al. "Non-cardiogenic pleural effusion after amlodipine intoxication and hyperinsulinemic therapy". *Medicine Science* 5.4 (2016): 1024-1026.

**Volume 6 Issue 3 March 2020**

**©All rights reserved by Bhavna P Singh, et al.**