

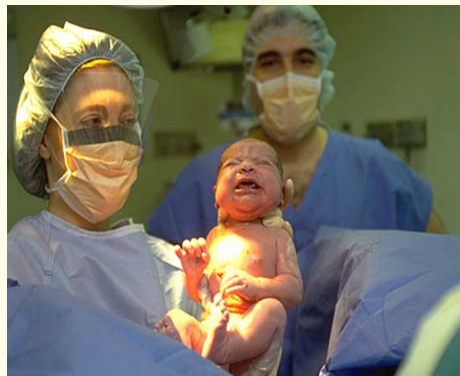## Anesthesia for Cesarean Section Baby Delivery in Parturient with Ebstein's Anomaly

**Kiro Churlinov\***

Department of Anesthesia, Reanimation and Intensive Care Medicine, Public Health Institution- University Clinic for Gynecology and Obstetrics, Skopje

**\*Corresponding Author:** Kiro Churlinov, Department of Anesthesia, Reanimation and Intensive Care Medicine, Public Health Institution- University Clinic for Gynecology and Obstetrics, Skopje.

**Received:** December 08, 2015; **Published:** December 14, 2015



*Figure 1*

### Abstract

#### Introduction

Wilhelm Ebstein is the first who described the clinical and anatomical features of an anomaly of the tricuspid valve in 1866. The septal and posterior cusps of the tricuspid valve are displaced downwards and are elongated, such that varying amount of right ventricle effectively forms part of right atrium.

#### Aim

This article describes the course and outcome of pregnancy in women with Ebstein's anomaly and discuss the related management issues.

#### Methods

Analysis, management and completion of pregnancy by cesarean section in woman with *Ebstein's* anomaly was carried out at our Clinic. The course of the pregnancy, disease and perinatal outcome were analyzed.

#### Case report presentation

28 years age parturient, with the second pregnancy, carried out from a small provincial town. She was undergoing to elective cesarean section. Preoperative evaluation included standard and additional clinical tools. An appropriate anaesthetic management protocol was performed. Monitoring of the postpartum period, the medical management of the same. The successful discharge from hospital was noticed, too.

### Conclusion

Meticulous planning, understanding of hemodynamic derangements, individualization and titration of drugs to the point of requirement and diligent care are an essential requisite for successful outcome. Under close supervision by the woman's obstetrician and cardiologist, the pregnancy outcome is usually favorable.

**Keywords:** *Ebstein's anomaly; Anesthetic management; Parturient; Cesarean section*

**Abbreviations:** RBBB: Right bundle branch block; WPW-sy: Wolf-Parkinson-White syndrome; SVES: Supra ventricular extra systoles; VES: Ventricular extra systoles; BP: Blood pressure; mmHg: Millimeters of mercury; HR: Heart rhythm; ECG: Electrocardiography; EHO: Echocardiography; CK: Creatinine kinase; LDH: Lactate dehydrogenase; SaO<sub>2</sub>: Saturation of oxygen; ASD: Atrial septal defect; ACE: Angiotensin-converting enzyme; EF: ejection fraction; NYHA: New York Heart Association.

### Introduction

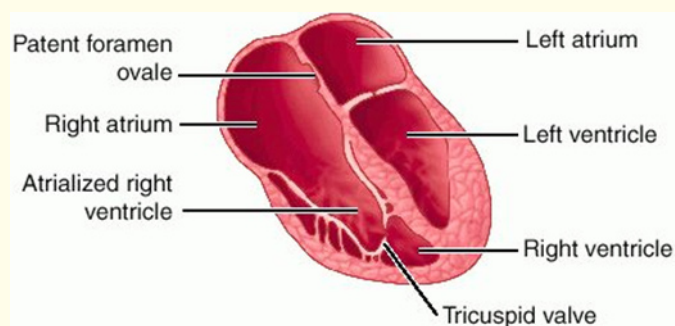
*Wilhelm Ebstein* first described the clinical and anatomical features of an anomaly of the tricuspid valve in 1866. Incidence is 1% of congenital heart defects (1 in 110,000 of the total population).

#### The main features are

- A. Dysplastic abnormalities of the tricuspid leaflet, moving downwards, with the result of significant tricuspid regurgitation.
- B. The proximal part of the right ventricle is "arterialized" - with thin walls and poor contractile but enlarged to huge right atrium (tricuspid atrialization of the right ventricle).

#### The severity of the disease depends on

- a. The degree of valvular abnormality.
- b. The presence (or not) the open foramen ovale, which results in right - left atrial shunt, cardiomegaly, right heart failure.
- c. The degree of pulmonary hypertension.
- d. Supraventricular and ventricular tachycardia, particularly in association with the WPW-sy, tachyarrhythmia, RBBB, the attacks of syncope, with or without RBBB (up to 25% of patients).
- e. Occurrence of paradoxical embolization, bacterial endocarditis, brain abscess. Congestive heart failure and sudden collapse are the most common causes of death.



*Figure 2*

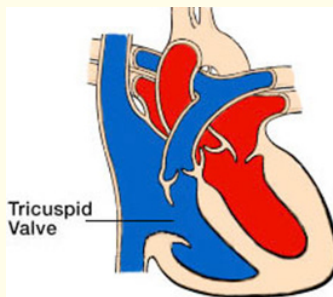
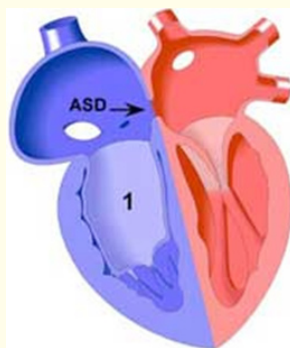


Figure 3



Ebstein's Anomaly

Figure 4

#### Additional anesthetic risks related to the pregnant woman

The onset of action of anesthetics is prolonged due to the dispersion of the same in increased right atrium. Each sub atmospheric pressure accidentally opened peripheral venous lines causes' paradoxical air embolism (when we are changing infusions, for example) [1]. Tachycardia is difficult to tolerate due to decreased preload (charge) of the small right ventricle, calculated to the vast right atrium.

Induced by anesthetics, hypotension leading to right-left atrial shunt, if foramen ovale is persistence. In case of maternal hypoxemia emphasizing of the pulmonary vasoconstriction and increased right-left shunt are occurred, too. Invasive monitoring, setting central venous catheter for monitoring of central venous pressure, leads to the risk of getting bacterial endocarditis, and a brain abscess [2]. Sometimes it is necessary to control the preload, which is also increased due to gestation–till 35%. The risk of tachyarrhythmia, SVES and VES, has significantly increased with the progression of pregnancy and associated with elevated levels of catecholamines in the same. Paradoxically reduced cardiac output at preeclampsia and hypertension due to increased systemic vascular resistance and right ventricular failure. It is increased to 40% in healthy parturients. Because of these changes, in patients with severe heart disease may develop congestive heart failure and acute heart failure as a result of increased demands of fetal-placentalentirety, because of increased blood flow during pregnancy, or if toxemia starts to develop [3].

#### Case report–close review

A 28 year old pregnant woman, from the small mountainous town Krusevo, was referred to our Clinic to complete baby delivery. A preeclampsia and previously noted *Ebstein's* anomaly was the main reasons of the hospital admission. Four years back she had an uncomplicated spontaneous baby delivery in the neighboring town Prilep. Her first complains was a mild dyspnoea and stenocardia, occasionally. The first examinations shows BP 130/80 mmHg; HR 105/min. Some preoperative evaluations were taken into consideration.

Auscultatory findings: Pulmo (lungs): Toughening vesicular regular breathing. Cor (heart): Discreet systolic and diastolic murmur in expressive projection of tricuspid and pulmonary valves, mid-diastolic murmurs with right parasternal thrill, along with widely split second heart sound [4]. She had irregular cardiac and obstetric controls in hers and neighboring town. She occasionally takes Tabl. Amiodarone á 150 mg (hetero anamnesis data taken from her husband). Laboratory findings, blood reports: Mild anemia and hypoproteinaemia, discreet leukocytosis. CK and LDH are easily elevated. The ECG shows sinus tachycardia rhythm, slight "P-pulmonale", the left heart axis, with RBBB [5].

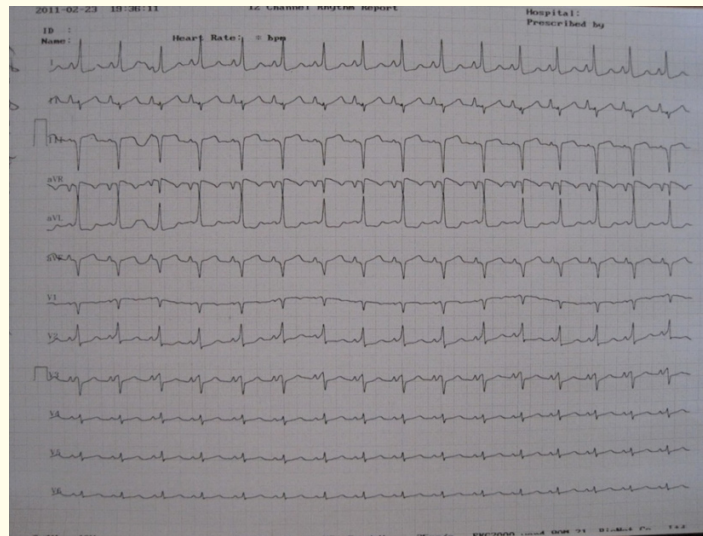


Figure 5

EHO findings point to suggesting signs of arterialization of the right ventricle. Septal tricuspid leaflet was dislocated in the right ventricle and rudimentary, while the lateral leaflet is hugely extended and amended. The right heart part is increased, the left one is suppressed and retail. Because of tachycardia, an assessment of regurgitated jets and possible existence of pulmonary hypertension are disabled [6]. Some indirect signs indicate volume overload on the right ventricle.

#### **Anesthetic management of parturient, a protocol of general anesthesia, modified and adjusted to the parturients medical condition**

Anesthesia was induced with Amp. Propofol 150 mg i.v given intermittently, gradually 3 X 50 mg within 1min. (2 mg/kg T.T.). Amp. Succinylcholine 80 mg i.v (1 mg/kg T.T.), immediately after Propofol application. Crash intubation, with cricoid pressure, follows. The maintenance of anesthesia was provided with a mixture of gases O<sub>2</sub>/air 50%: 50% + Isoflurane 0.8 vol. till 1,2 vol.%, the first 10 min. Amp. Rocuronium bromide (Esmeron) 30 mg i.v (0.4 mg/kg T.T.). Further anesthetic management was continued after baby delivery. Amp. Fentanyl 0,2 mg i.v (0.5 µcgr/kg TT) – gradually 2 x 0.1 mg, within 7-8 minutes. Amp. Ceftriaxone (Lendacin) á 2 gr. i.v., slow application. Surgery lasted for duration of 40 minutes. At the end of surgery, when the patient had respiratory attempts, neuromuscular block Adewas reversed with Neostigmine 2.5 mg and atropine 1 mg. Recovery and extubation was smooth and uneventful.

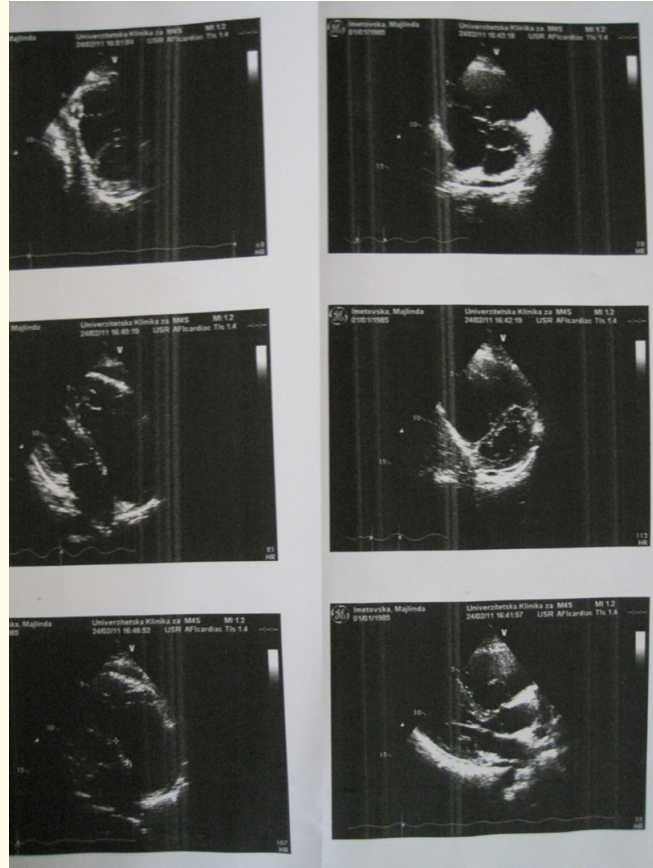

Figure 6

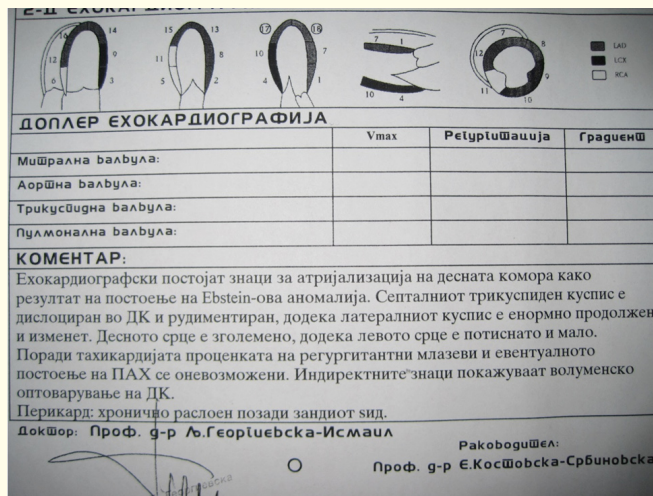


Figure 7: Original EHO presentation, comment on finding EHO (Macedonian transcript). Everything leads to conclusion of Ebstein's anomaly.

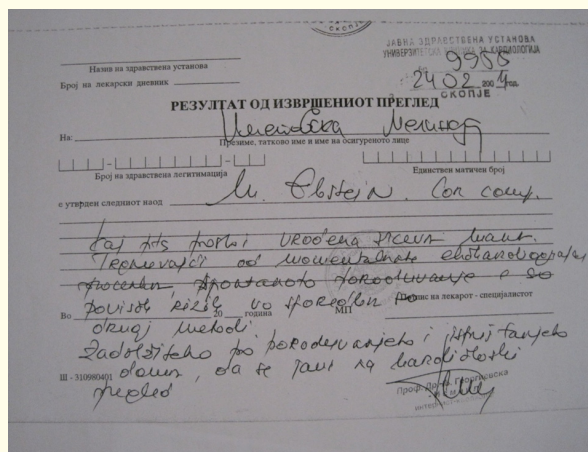
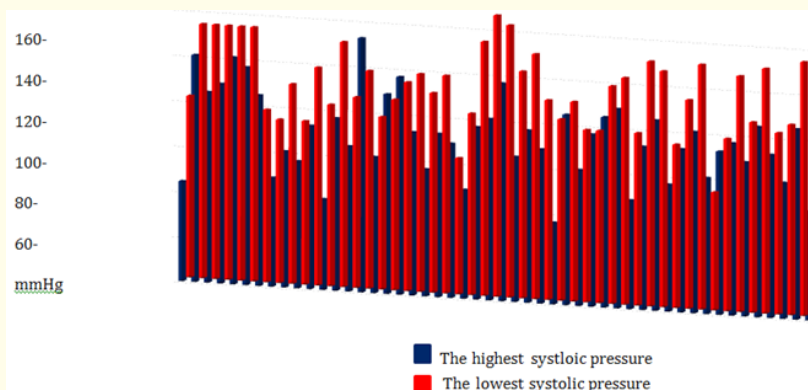


Figure 8: Final, preoperative cardiological diagnosis (Macedonian and Latin transcript).

Average values of systolic pressure (time = 40 minutes)



Time: 1 5 10 15 20 25 30 35 40

Figure 9: Intraoperative monitoring parturient, some hemodynamic parameters.

The highest peak of BP was 165/105 mmHg; HR = 122/min; immediately post intubation. The lowest peak BP was 118/76 mmHg; HR = 78/min.; after baby delivery, amp. Fentanyl 0.1 mg i.v and application of amp. Syntocinone 20 i.e./to infusion. SaO<sub>2</sub>: 96-98%. Intraoperative EKG correlated to diagnosis of the parturients condition. The male alive baby was delivered, 3750 gr/52 cm, Apgar score 7/8/8, pH = 7, 32.

Postoperative cardiorespiratory stable, was placed in Fowler's position.

Besides the usual protocols, postoperative therapy included adequate cardiac therapy. The first day: Amp. Clexane (enoxaparin) 2 X 60 mg subcutaneously; then 2 X 40 mg, the second postoperative day until hospital discharges. Amp. Furosemide (Lasix) 2-3 X 5 mg i.v Tabl. Hydrochlorothiazide á 25 mg, the second postoperative day until hospital discharge. Tabl. Skopryl (Lisinopril) á 5 mg, the first postoperative day. Tabl. Verapamil á 240 mg; in case of HR > 100/min [7]. Infusion solutions, crystalloids 25 ml/kg TT + 1.000 ml/24h

orally. Discharged from hospital 5-th postoperative day, with recommendations for regular cardiac controls and advice to control further family expansion.

### Discussion

The degree of abnormality of the right ventricular function and size of the ASD are the major determinant of the severity of the parturients condition. Hypotension is usually avoided if this complication can be treated with fluids and vasopressors that may result in further instability in these patients. Excessive fluid administration can lead to heart failure or may increase the right to left shunt and hypoxemia. Ephedrine is a potent beta agonist, so it can lead to supraventricular tachycardia in patients. Ephedrine does not affect a uterine vasoconstriction and not compromised fetal oxygenation, too. General anesthesia rarely causes hypotension and endotracheal intubation allows control of oxygen delivery to parturients lung. Anesthetic for cardiovascular stability: etomidate, propofol, fentanyl or alfentanil, and rocuronium and vecuronium, are suitable. They minimize tachycardia and hypotension. If used central venous catheter, CVC for preload monitoring, its end spot should be in vena cava sup. Hemorrhage, along with excessive fluid resuscitation, are generally poorly tolerated. The combined effects of an increase in circulating catecholamines, hemodynamic instability and hypoxemia among parturients with Ebstein's anomaly are associated with premature birth, low birth weight and neonatal modest results. 2-14% of these babies have congenital heart diseases. After baby delivery and contraction of the uterus, stroke volume increased again. Uterine blood transfusions as their own, is diverted into systemic circulation. Then it's possible to happen a cardiac congestion.

Diet recommendation: diet with low sodium level, because of a risk of fluid overload. Epidural (but not spinal) anesthesia is a possible options for anesthesia, but only among parturients with borderline and subnormal values of EF ( $\geq 60\%$ ), classification of NYHA I, plus all other indications. Possible hydration with sol. Ringer 500 ml, preoperatively. Therapy considerations: antiarrhythmic, ACE-inhibitors, diuretics, cardio tonics.

### Conclusion

Extensive preoperative evaluation and preparation, regular antepartum, cardiac and obstetric controls, fetal echocardiogram in the 18<sup>th</sup> week of pregnancy, consultation with the anesthesiologist-multidisciplinary approach. Necessary hospitalization in a tertiary health institution, clinic. Prophylactic antibiotics administration, because of a risk of infective endocarditis. The baby can usually be born vaginally if the mother belongs to NYHA I-II classification. For those with NYHA III-IV the pregnancy is not recommended. Cesarean delivery is not usually necessary only for cardiac diseases. Indications of the same is exclusively decision of the obstetric.

### Bibliography

1. Grover VK, *et al.* "Anesthesia for incidental surgery in a patient with Ebstein's anomaly". *Indian Journal of Anaesthesia* 35.3 (1987): 223-228.
2. Samina Khaliloddin Khatib, *et al.* "Anesthetic implications of Ebstein's anomaly". *Anaesthesia, Pain and Intensive care* 16.1 (2012): 60-63.
3. Potouridou M, *et al.* "Epidural anesthesia for cesarean delivery in a parturient with Ebstein's anomaly". *European Journal of Anaesthesiology* 30 (2013): 166.
4. Majid Saleem. "Management of a parturient with history of Epstein's anomaly and protein S deficiency". *The Internet Journal of Anesthesiology* 26.1 (2009).
5. Chagede P, *et al.* "Successful pregnancy outcome in a patient with Ebstein's anomaly". *Journal of Postgraduate Gynecology & Obstetrics* 2.9 (2015).
6. Marla A Mendelson. "Pregnancy in the woman with preexisting cardiovascular disease". *The International Federation of Gynecology and Obstetrics* (2008).
7. Macfarlane AJ, *et al.* "Caesarean section using total intravenous anesthesia in a patient with Ebstein's anomaly complicated by supraventricular tachycardia". *International Journal of Obstetric Anesthesia* 16.2 (2007): 155-159.

---

**Citation:** Kiro Churlinov. "Anesthesia for Cesarean Section Baby Delivery in Parturient with Ebstein's Anomaly". *EC Anaesthesia* 2.4 (2015): 187-194.

Volume 2 Issue 4 December 2015

© All rights are reserved by Kiro Churlinov.